




Charles Stewart

1. M. W. 1865. 11.













Digitized by the Internet Archive  
in 2012 with funding from  
Open Knowledge Commons and Harvard Medical School

<http://archive.org/details/photographsofsur05unit>





1983

(No. 10)  
12.5.21

Pl. V. Gray Sand boards.



*United States*

PHOTOGRAPHS

OF

SURGICAL CASES AND SPECIMENS.

---

PREPARED BY DIRECTION OF THE SURGEON GENERAL,

BY

Brevet Lieutenant Colonel GEORGE A. OTIS, Assistant Surgeon, U. S. A.,

CURATOR OF THE ARMY MEDICAL MUSEUM.

---

WASHINGTON:

SURGEON GENERAL'S OFFICE.



1. Mw. 1865. 2

## CONTENTS OF VOLUME V.

Page.	No of Photo.	NAME.	RANK, REG'T, Etc.	No. of Specimen from which taken.	DESCRIPTION.
1	201	Massey, William T.	Pvt. Co. I, 7th Ill.	.....	Result of an excision of a portion of the left humerus.
2	202	Fulton, Henry D.	Pvt. Co. E, 39th Ind.	.....	Successful excision of the head of the left humerus.
3	203	Swift, Eben E.	Pvt. Co. A, 11th Me.	81	Stump of a reamputation at the right hip.
4	204	Shutter, Allison	Drum Co. C, 7th Pa. Res.	.....	Recovery after partial excision of the left knee-joint.
5	205	Decker, Sam'l H.	Pvt. Co. I, 4th U. S. A.	.....	Showing loss of the forearms.
6	206	Guy, Franklin	Citizen	.....	Loss of forearms by machinery.
7	207	Unknown soldier		.....	Amputation of both arms.
8	208	Brink, John	Pvt. Co. K, 11th Pa.	.....	Excision of proximal extremitiy of right humerus.
9	209	Powers, Thomas	Pvt. Co. D, 30th Me.	2619	Old united depressed fracture of the cranium.
10	210	Beebe, Dwight	Lt. 3d N. Y. V. V.	.....	Successful excision at the right hip-joint.
11	211	Unknown		2870	Penetrating gunshot fracture of cranium.
12	212	Volk, Edward	Pvt. Co. D, 55th O.	276	Gunshot fraeture of the cranium.
13	213	Brennen, Thos.	Pvt. Co. I, 65th N. Y.	3413	Gunshot penetrating fracture of frontal bone.
14	214	Unknown		830	Cranium perforated by a musket ball.
15	215	Unknown		3251	" " "
16	216	Unknown		3254	Gunshot fracture of skull.
17	217	<i>Knoulton, Chas.</i>	Capt. 10th La. -	.....	Successful intermediate excision of right knee-joint.
18	218	Brown, John	Pvt. Co. I, 9th Minn.	?	Stomach perforated by musket ball.
19	219	Unknown		4832	Hypertrophied prostate gland and bladder with calculi.
20	220	Unknown		852	Ligamentous preparation of foot affected with talipes.
21	221	Unknown		5188	Luxation forward of the astragalus.
22	222	Fancy, William	Freedman	5256	Aorta ligated for aneurisum.
23	223	Various patients	Enlisted men	.....	Vesical concretions resulting from gunshot injuries.
24	224	Unknown		.....	Urinary calculi.
25	225	Brown, Elijah	Freedman	3648	Transverse fracture of femur.
26	226	Unknown		5484	Right femur of Mound Builder united after fracture.
27	227	Donnelly, Reuben	Pvt. Co. A, 21st O.	319	Distal extremity of right femur perforated and fractured by a musket ball.
28	228	Jones, Jesse M.	Pvt. Co. K, 21st Ind.	5558	Portion of right femur showing union after gunshot injury.
29	229	Bowen, C. H.	Pvt. Co. A, 27th Ind.	4914	Portion of left femur successfully amputated.
30	230	Wager, James H.	Pvt. Co. H, 125th N. Y.	3168	Showing oblique fracture of right femur from a musket ball.
31	231	Barrett, Grey Y.	Pvt. Co. F, 5th N. H.	536	Portions of right femur after an osteoplastic operation and a secondary amputation.
32	232	Holmes, Thomas	Pvt. Co. D, 1st Mich.	2486	Longitudinal fracture of left femur from gunshot injury.
33	233	Unknown		5251	Reproduction of metacarpals and phalanges after necrosis.
34	234	Maynard, Herman L.	Pvt. Co. C, 17th N. Y.	.....	Right arm after a successful excision.
35	235	Welch, Thomas	Pvt. Co. F, 6th Me.	.....	Partial recovery after gunshot fracture of left thigh.
36	236	Murtha, Michael	Pvt. Co. H, 159th N. Y.	.....	Partial recovery after gunshot fracture of right thigh.
37	237	Tyler, O. R.	Lt. Co. I, 2d Conn. H. A.	.....	Successful excision of a portion of left tibia.
38	239	<i>Powell, M. D.</i>	Pvt. Co. H, 26th Ala.	3841	Left femur showing result of a gunshot wound.
39	238	Unknown		5118	Luxation of the Atlas.
40	240	Unknowu		5119	" "
41	241	Unknown		3100-144	Tubular sequestra.
42	242	Connor, Geo. A.	Lt. Co. A, 7th W. Va.	4382	Portion of right femur after gunshot fracture.
43	243	Unknown		.....	Sequestra from femurs.
44	244	Keith, John E.	Pvt. Co. C, 13th Mass.	244	Condition of left femur after gunshot fracture.
45	245	Manley, S.	Pvt. Co. A, 63d N. Y.	1935	Condition of right femur after gunshot fracture.
46	246	Jones, Josiah	Pvt. Co. D, 12th N. H.	.....	Partial recovery after gunshot fracture of left femur.
47	247	Schranz, John	Pvt. 7th Aus. Feldjägers.	.....	Successful secondary amputation at left hip-joint.
48	248	Read, C. F.	Pvt. Co. I, 37th U. S. I.	.....	Successful secondary excision at left hip-joint.
49	249	Unknown		.....	Fragments of bone removed by operation.
50	250	Bush, H. P.	Pvt. Co. F, 1st Mass. C.	.....	Fractured bones of right and left forearm.





SURGICAL PHOTOGRAPH NO. ....

*Prepared under the supervision of*  
ASSISTANT SURGEON GEORGE A. OTIS, U. S. A.  
BY ORDER OF THE SURGEON GENERAL.

**WAR DEPARTMENT.**  
SURGEON GENERAL'S OFFICE, ARMY MEDICAL MUSEUM.

# Surgeon General's Office.

## ARMY MEDICAL MUSEUM.

PHOTOGRAPH NO. 201. *Results of an Excision of the Head and Upper Third of the Shaft of the Left Humerus for Gun-shot Fracture, complicated by a Perforation of the Scapula.*

William T. Massey, private Co. I, 7th Illinois Volunteers, was wounded at the battle of Altoona, Georgia, October 5, 1864, by a conoidal ball entering anterior aspect of arm and emerging through the body of scapula, below the spine, producing a compound comminuted fracture at upper third of left humerus. Seven hours after the reception of the injury, while on the field, Surgeon Sylvester H. Sawyers, 36th Iowa Volunteers, excised the upper third of the shaft, removing four and a half inches together with the head of the humerus, through a linear incision between the biceps and deltoid muscles. The wound healed well, with flexion of fore-arm impaired by contraction of the injured triceps extensor. The wound through the scapula was yet open, and the arm useless for labor when the man was discharged the service. His arm was shortened one and a half inches, but was nearly normal in size. He was discharged from service March 12, 1865, while at Chattanooga, Tennessee. An apparatus was furnished him by Dr. E. D. Hudson three years and eleven months after the excision, which greatly improved the power of moving the limb.

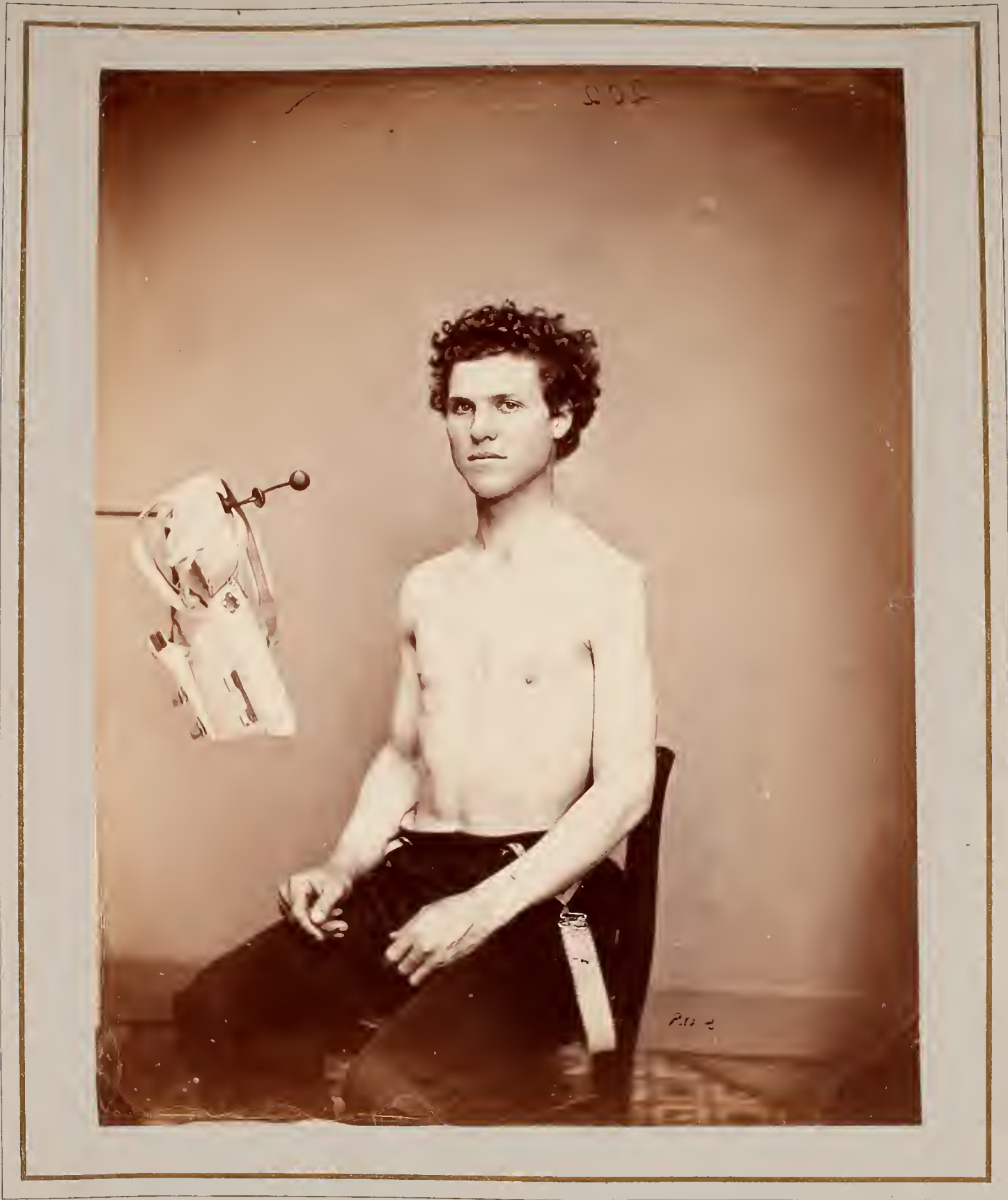**Photographed at the Army Medical Museum.**

BY ORDER OF THE SURGEON GENERAL:

GEORGE A. OTIS,

*Bvt Lt. Col. and Ass't Surg. U. S. A., Curator A. M. M.*





SURGICAL PHOTOGRAPH NO. ....

*Prepared under the supervision of*  
ASSISTANT SURGEON GEORGE A. OTIS, U. S. A.  
BY ORDER OF THE SURGEON GENERAL.

**WAR DEPARTMENT.**  
SURGEON GENERAL'S OFFICE, ARMY MEDICAL MUSEUM.

Surgeon General's Office.  
ARMY MEDICAL MUSEUM.

PHOTOGRAPH No. 202. *Excision of the Head of Left Humerus for Gunshot Injury.*

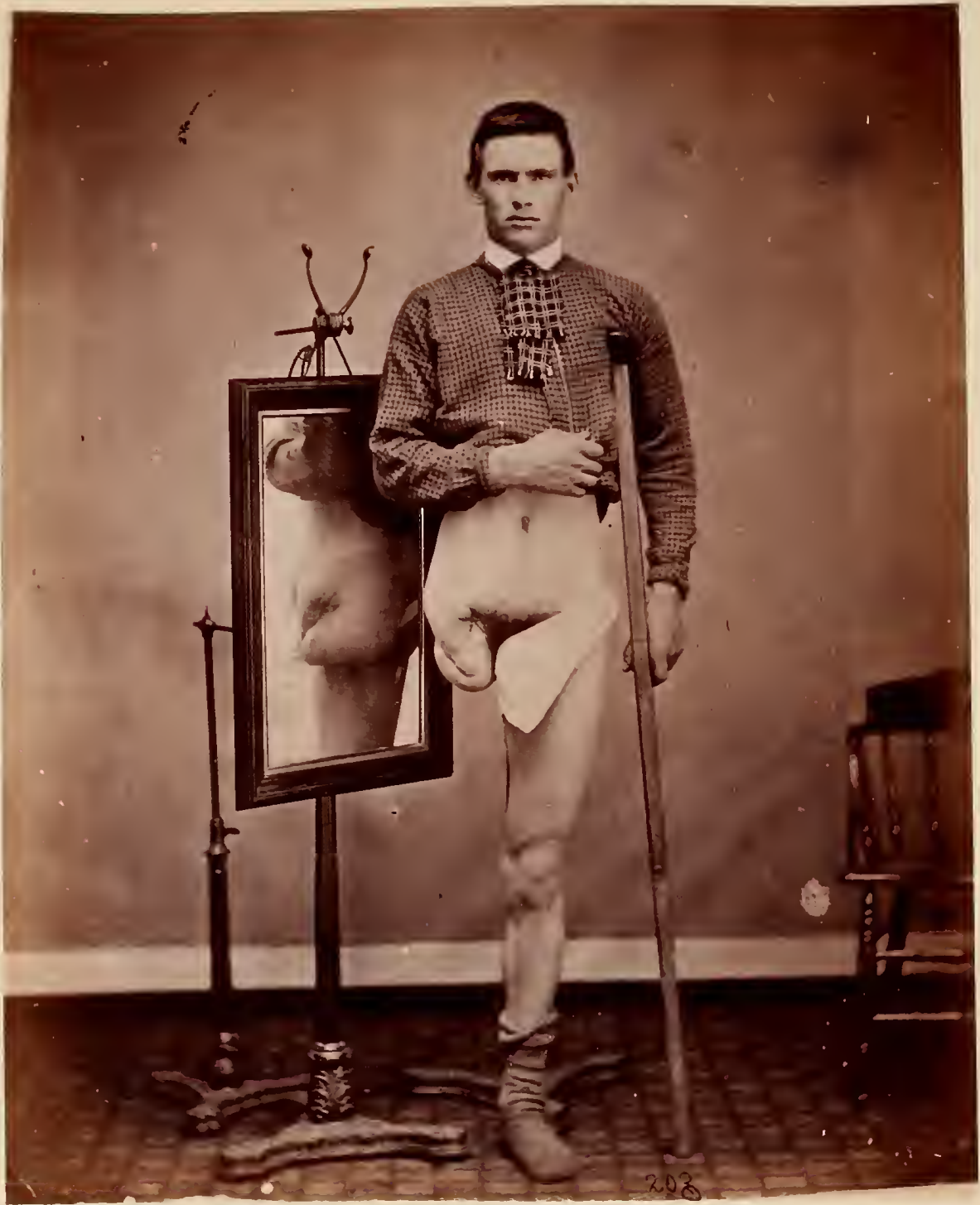Henry D. Fulton, private Co. E, 30th Indiana Volunteers, was wounded at the battle of Chickamauga, Georgia, September 19, 1863, by a canister shot. The missile entered at the surgical neck of the left humerus, passed upward and backward, comminuted the head of the humerus, and made its exit beneath the base of the acromion. The patient was sent to the Cumberland hospital at Nashville, Tennessee. Extensive exfoliation followed, and abscesses burrowed beneath the clavicle and scapula. On November 1, 1863, Assistant Surgeon C. F. Haynes, U. S. V., excised the head of the left humerus, the outer portion of the acromion process, and a portion of the articular surface of the scapula, through a linear incision on the anterior aspect of the arm. The case progressed favorably, suppuration beneath the clavicle and scapula ceased, the external wound cicatrized, and his general health rapidly amended. Unfortunately, firm ankylosis took place between the scapula and upper extremity of the humerus, and the muscles of the shoulder wasted from disuse. The patient was transferred to hospital at Madison, Indiana, on March 11, 1864, and was discharged from service April 22, 1864. In September, 1868, this pensioner went to New York, and was provided with an apparatus by Dr. E. D. Hudson, who reported that the shortening of the arm was about half an inch, the motions of the forearm and hand were normal, that the muscles of the shoulder were much atrophied, and that the only motion of the shoulder was the limited movements permitted by the scapula following the humerus. Dr. Hudson was of the opinion that the apparatus which he applied mechanically aided muscular action to a satisfactory degree.

Photographed at the Army Medical Museum.

BY ORDER OF THE SURGEON GENERAL:

GEORGE A. OTIS,

*Br't Lt. Col. and Ass't Surg. U. S. A., Curator A. M. M.*



SURGICAL PHOTOGRAPH NO. ....

*Prepared under the supervision of*  
ASSISTANT SURGEON GEORGE A. OTIS, U. S. A.  
BY ORDER OF THE SURGEON GENERAL.

\*\*\*  
**WAR DEPARTMENT.**  
SURGEON GENERAL'S OFFICE, ARMY MEDICAL MUSEUM

# Surgeon General's Office.

## ARMY MEDICAL MUSEUM.

PHOTOGRAPH No. 203. *Stump of a Reamputation at the Right Hip, Two and a half years Subsequent to the Operation.*

Private Eben E. Smith, Co. A, 11th Maine Volunteers, aged nineteen years, was wounded at the engagement at Deep Bottom, near Drury's Bluff, Virginia, on August 16, 1864, by a musket ball, which fractured the head of the right tibia. He was admitted to the U. S. General Hospital, at Beverly, New Jersey, on August 22, 1864. On September 12th, the thigh was amputated at the lower third. On January 19, 1865, re-amputation at the hip was performed by Acting Assistant Surgeon J. H. Packard. On January 27th, there was secondary hæmorrhage, and the external iliac was tied. On May 27th, he was discharged from service, well and strong. He was received as a pensioner in the Eastern Branch of the U. S. Military Asylum for Disabled Volunteer Soldiers, in May, 1867. On July 11, 1867, Surgeon B. B. Breed had the negative taken from which the photograph is printed, and reported Smith to be in excellent health. In the spring of 1870 his health remained good. He had been pensioned and supplied with an artificial limb. The necrosed upper extremity of the femur is represented in the wood cut. A more detailed account of the earlier history of the case will be found with Photograph No. 29.



Photographed at the Army Medical Museum.

BY ORDER OF THE SURGEON GENERAL:

GEORGE A. OTIS,

*Br't Lt. Col. and Ass't Surg. U. S. A., Curator A. M. M.*



SURGICAL PHOTOGRAPH NO. . . . .

*Prepared under the supervision of*  
ASSISTANT SURGEON GEORGE A. OTIS, U. S. A.  
BY ORDER OF THE SURGEON GENERAL.

WAR DEPARTMENT.  
SURGEON GENERAL'S OFFICE, ARMY MEDICAL MUSEUM.

Surgeon General's Office.  
ARMY MEDICAL MUSEUM.

PHOTOGRAPH No. 204. *Recovery after Shell Wound of the  
Knee-Joint treated by Partial Primary Excision.*

Allison Shutter, Drummer, Co. C, 7th Pennsylvania Reserves, received, in one of the earlier of the seven days' battles before Richmond, in June, 1862, a shell wound of the left knee-joint. He was taken prisoner, and while he was in the enemy's lines it was decided that primary excision of the knee-joint should be performed on the field. The operation was commenced, but was interrupted by an advance of the Union troops, who regained the ground they had lost earlier in the day. The parts were brought in apposition, and the limb secured to a splint, and the patient was sent to Fort Monroe, and admitted to Hygeia Hospital on June 30th. On July 6th he was sent to Philadelphia on the steamer Daniel Webster. He was admitted, on July 7th, to the Satterlee Hospital. The wound cicatrized, and left a comparatively useful limb. This soldier was discharged February 5, 1863, by Surgeon I. I. Hayes, U. S. V., for "lameness resulting from a shell wound of the left knee." His name does not appear on the Pension List.

Photographed at the Army Medical Museum.

BY ORDER OF THE SURGEON GENERAL:

GEORGE A. OTIS,

*Br't Lt. Col. and Ass't Surg. U. S. A., Curator A. M. M.*



SURGICAL PHOTOGRAPH NO. . . . .

*Prepared under the supervision of*  
ASSISTANT SURGEON GEORGE A. OTIS, U. S. A  
BY ORDER OF THE SURGEON GENERAL.

**WAR DEPARTMENT.**  
SURGEON GENERAL'S OFFICE, ARMY MEDICAL MUSEUM

Surgeon General's Office.  
ARMY MEDICAL MUSEUM.

PHOTOGRAPH No. 205. *Double Amputation of the Forearms for Injury caused by the Premature Explosion of a Gun.*

Private Samuel H. Decker, Co. I, 4th U. S. Artillery, while ramming his piece at the battle of Perryville, Kentucky, October 8, 1862, had half of his right forearm, and somewhat less of the left, blown off by the premature explosion of the gun. At the same time his face and chest were badly burned. Five hours after the accident, both forearms were amputated by the circular method, about the middle, by an Assistant Surgeon of the regular army whose name he cannot recall. He lay in the field hospital at Perryville until the wounds were partially cicatrized, when, on November 1st, he went to Louisville, Kentucky, and, on the 3d of November, 1862, he was discharged the service. About the middle of January, 1863, the stumps were completely healed. In the Autumn of 1864, Mr. Decker began to make experiments for providing himself with artificial limbs. He produced, in March, 1865, an apparatus hitherto unrivaled for its ingenuity and utility. He receives a pension of \$300.00 per year, and is a doorkeeper at the House of Representatives. On November 29, 1867, Mr. Decker visited the Army Medical Museum, where a number of photographs of his stumps were made. With the aid of his ingenious apparatus he is enabled to write legibly, to pick up any small objects, a pin for example, to carry packages of ordinary weight, to feed and clothe himself, and in one or two instances of disorder in the Congressional gallery has proved himself a formidable police officer.

**Photographed at the Army Medical Museum.**

BY ORDER OF THE SURGEON GENERAL:

GEORGE A. OTIS,

*Br't Lt. Col. and Ass't Surg. U. S. A., Curator A. M. M.*





SURGICAL PHOTOGRAPH NO. ....

*Prepared under the supervision of*  
ASSISTANT SURGEON GEORGE A. OTIS, U. S. A.  
BY ORDER OF THE SURGEON GENERAL.

**WAR DEPARTMENT.**  
SURGEON GENERAL'S OFFICE, ARMY MEDICAL MUSEUM.

Surgeon General's Office.  
ARMY MEDICAL MUSEUM.

PHOTOGRAPH, 206. *Amputation of Forearms for Injury by a  
Brick Machine.*

Franklin Guy, brick maker, aged thirty-four years, had his hands caught in a steam press, October 12, 1868. The right hand was torn off just above the wrist, and the left hand at the wrist. He was conveyed to Providence Hospital, Washington, D. C., and five and a half hours after the reception of the injuries both forearms were amputated a little above the carpus by Dr. J. Ford Thompson. No hæmorrhage had taken place before the operation. The wounds healed with great promptitude. On October 23, the patient left the hospital, and in three and a half weeks, both stumps were completely healed. Mr. Guy visited the Army Medical Museum on January 13, 1869, and a photograph of the stumps was made, and he was advised to obtain the artificial limbs devised by Mr. Decker, a sufferer from the same mutilation, figured in Photograph 205.

Photographed at the Army Medical Museum.

BY ORDER OF THE SURGEON GENERAL:

GEORGE A. OTIS,

*Br't Lt. Col. and Ass't Surg. U. S. A., Curator A. M. M.*



SURGICAL PHOTOGRAPH NO. ....

*Prepared under the supervision of*  
ASSISTANT SURGEON GEORGE A. OTIS, U. S. A.  
BY ORDER OF THE SURGEON GENERAL.

WAR DEPARTMENT.  
SURGEON GENERAL'S OFFICE, ARMY MEDICAL MUSEUM.

Surgeon General's Office.  
ARMY MEDICAL MUSEUM.

PHOTOGRAPH No. 207. *Amputation of Both Arms for Gunshot Injury.*

This photograph represents a discharged soldier of many months, who was seen at the corner of Seventh street and Pennsylvania avenue, with a one armed companion, who turned a barrel organ, while this more mutilated man had suspended about his neck a chest for alms, the lid of which he opened by a backward movement of his left shoulder. He was photographed at the Museum in 1869. He gave his name as Sergeant Warden; but a history of the case is not found on the Surgical Records. After a long search it has been impracticable to identify the case with any of those of double amputation reported at this Office. A newspaper item states that this man was found dead in the streets of Buffalo in 1869.

Photographed at the Army Medical Museum.

BY ORDER OF THE SURGEON GENERAL:

GEORGE A. OTIS,  
*Ass't Surg. U. S. A., Curator A. M. M.*



SURGICAL PHOTOGRAPH NO. . . . .

*Prepared under the supervision of*  
ASSISTANT SURGEON GEORGE A. OTIS, U. S. A.  
BY ORDER OF THE SURGEON GENERAL.

WAR DEPARTMENT.  
SURGEON GENERAL'S OFFICE, ARMY MEDICAL MUSEUM.

# Surgeon General's Office.

## ARMY MEDICAL MUSEUM.

PHOTOGRAPH No. 208. *Excision of the Head and three inches of the Shaft of the Right Humerus for Gunshot Injury.*

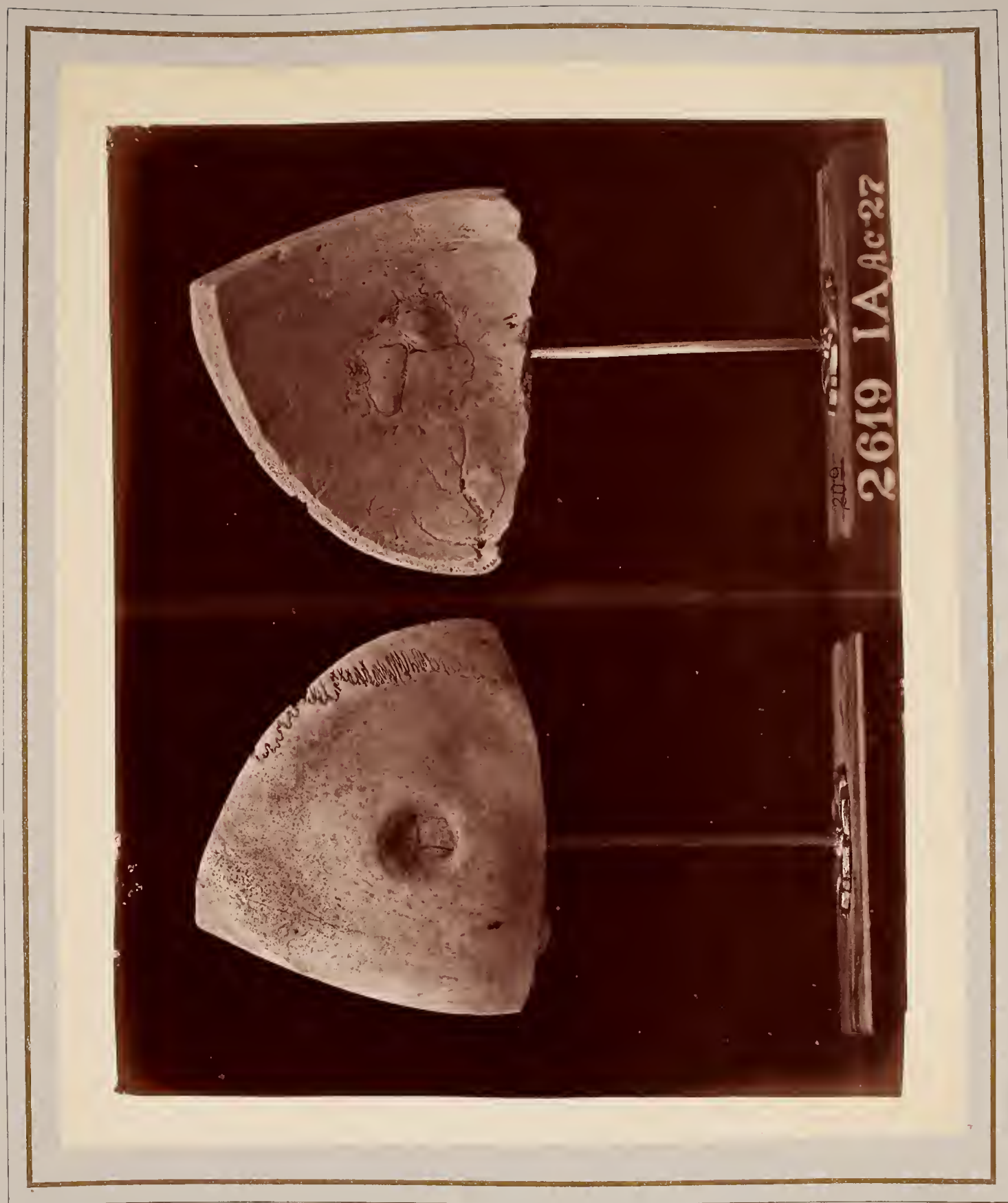Private John Brink, Co. K, 11th Pennsylvania Cavalry, aged nineteen years, was wounded May 21, 1863, by a musket ball, which struck two inches below the right acromian process and shattered the surgical neck of the humerus. He was with a scouting party which was fired upon by a guerilla band, near Windsor, Virginia. He was taken at once to the regimental hospital at Suffolk, and a few hours after the reception of the injury, Surgeon George C. Harlan, 11th Pennsylvania Cavalry, excised the upper extremity of the bone through a straight incision on the outside of the arm. Surgeon T. H. Squires, 89th New York, who saw the patient on June 2d, states that the patient was then doing very well, though he was pale; and adds that Dr. Harlan observed that he had lost much blood before and during the operation, and also mentioned that the splintering did not extend beyond the anatomical neck of the bone. On June 23d the patient was transferred to Chesapeake Hospital. On September 23d he was discharged, his disability being rated at one-half by Surgeon A. E. Stocker, U. S. Vols., and was pensioned from that date. He went to reside at Kingston, Luzerne County, Pennsylvania. The pension examining surgeon for that district, Dr. G. Urquhart, reported to the Pension Office, September 22, 1866, that the arm was "entirely powerless to raise it or to use it in any other position than hanging by his side." It is probable that the examiner was deceived; for the pensioner was employed as a telegraph operator, and always used his right hand, and could readily place that hand on his left shoulder. In March, 1868, Dr. Harlan, examined the patient in Philadelphia, and found that the arm was shortened one inch. Two or three inches of the upper extremity of the shaft must have been regenerated. The arm was nearly normal in size. A few months subsequently Brink visited the Army Medical Museum, and was examined by Dr. Otis and others, and it was found that the results of the excision were very satisfactory. The motion of the upper arm was better preserved than after most cases of excision of the head of the humerus, and the functions of the forearm and hand were unimpaired.

Photographed at the Army Medical Museum.

BY ORDER OF THE SURGEON GENERAL:

GEORGE A. OTIS,

*Bvt Lt. Col. and Ass't Surg. U. S. A., Curator A. M. M.*



SURGICAL PHOTOGRAPH NO. . . . .

*Prepared under the supervision of*  
ASSISTANT SURGEON GEORGE A. OTIS, U. S. A.  
BY ORDER OF THE SURGEON GENERAL.

WAR DEPARTMENT.  
SURGEON GENERAL'S OFFICE, ARMY MEDICAL MUSEUM

Surgeon General's Office,  
ARMY MEDICAL MUSEUM.

PHOTOGRAPH No. 209. *Old United Depressed Fracture of the Cranium.*

This photograph represents the inner and outer aspects of a segment of a cranium, deeply indented at a point above and external to the right frontal eminence, and exhibits the repair of a deeply depressed fracture of both tables. Outwardly there is a smooth, circular, cup like depression, and within three firmly consolidated triangular plates, the edges smoothed off, and the fissures filled in with callus. Unfortunately there is no account of this accident on record. The patient, Private Thomas Powers, Co. D, 30th Maine Volunteers, aged forty-one years, was admitted to the Jarvis Hospital, Baltimore, Maryland, on April 5, 1865, suffering from an attack of typhoid fever, for which he was treated. He had nearly recovered, when he suddenly grew worse again, and a decided inability to raise his right arm and leg could be noticed. These symptoms gradually increased, and at last his head was turned to the left side, and also his tongue, and he was entirely unable to move his right side. He remained in this condition for several days, being unable to take much medicine or nourishment, and died on the 2d of July, 1865. At the autopsy, the brain was found turgid with blood, with many minute extravasations. The right vertebral artery was plugged by a clot. The specimen, No. 2619, Surgical Section, was presented by Surgeon De Witt C. Peters, U. S. Army. In endeavoring to trace this case, it has been found that this patient was a "substitute," that he was "mustered in" July 28, 1864. and probably did not reach the battle field till many weeks afterwards, if at all; but it must have required a period of much more than twelve months to have brought about the extent of repair that is here observed. The closure of solutions of continuity of the skull by complete ossification rarely takes place, and when it does, always occupies, as Rokitsansky observes, a very long period. It is probable that long prior to his enlistment as a substitute that this man had received a punctured fracture of the frontal region, which consolidated, and escaped the notice of the examining surgeon, as it subsequently escaped the notice of the hospital physician.

Photographed at the Army Medical Museum.

BY ORDER OF THE SURGEON GENERAL:

GEORGE A. OTIS,

*Br't Lt. Col. and Ass't Surg. U. S. A., Curator A. M. M.*





SURGICAL PHOTOGRAPH NO. ....

*Prepared under the supervision of*

ASSISTANT SURGEON GEORGE A. OTIS, U. S. A.  
BY ORDER OF THE SURGEON GENERAL.

WAR DEPARTMENT,  
SURGEON GENERAL'S OFFICE, ARMY MEDICAL MUSEUM

Surgeon General's Office.  
—+—  
ARMY MEDICAL MUSEUM.  
—+—

PHOTOGRAPH No. 210. *Successful Primary Excision of the Head and Neck of the Right Femur.*

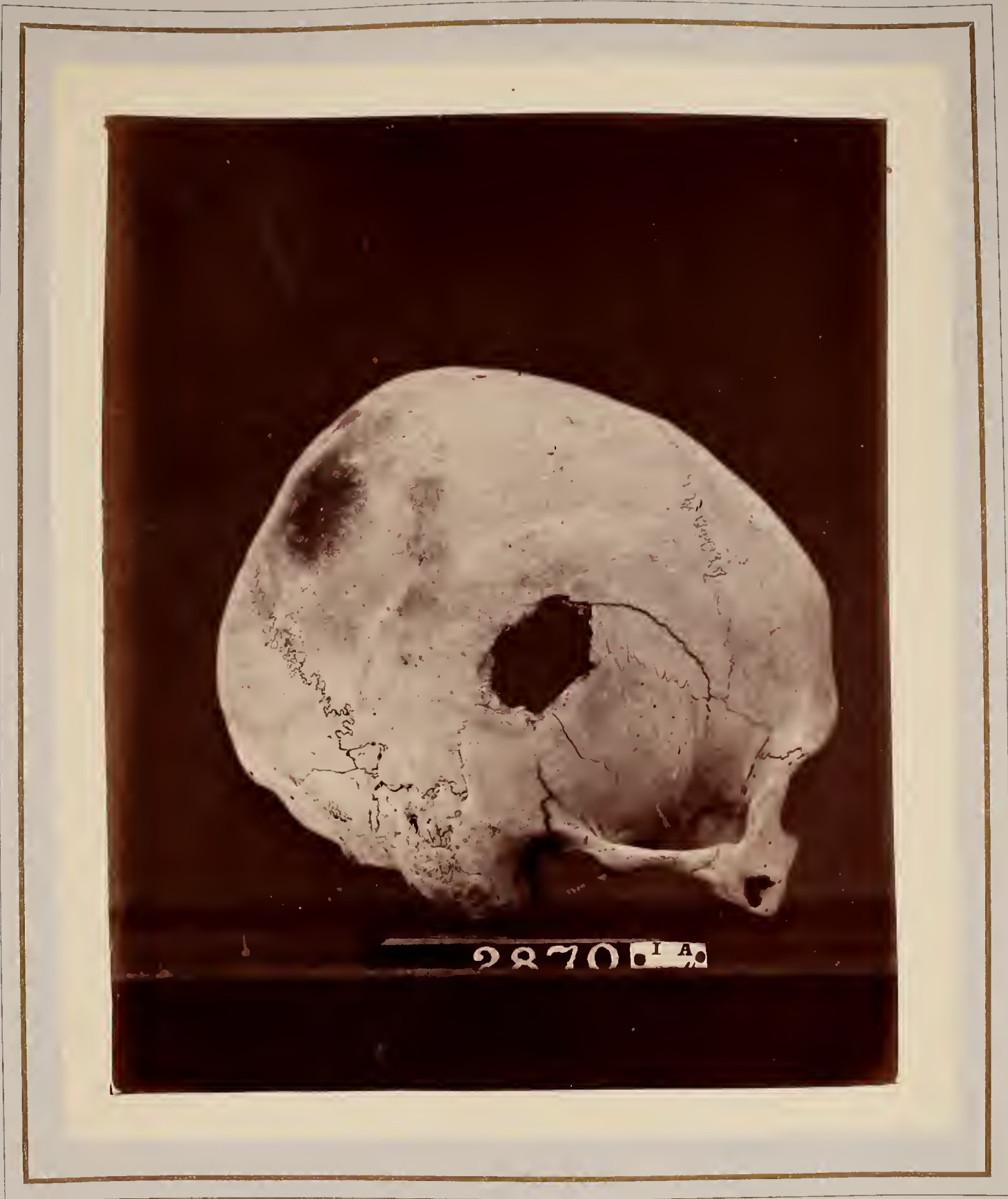This case is fully described in the Report on Excisions at the Head of the Femur for Gunshot Injury in Circular No. 2, S. G. O., January, 1869, Case XXX, page 32. There has been much dispute as to who should have the credit of the operation. It is claimed by Dr. N. Y. Leet, late Surgeon 76th Pennsylvania Volunteers, and by Surgeon C. M. Clark, 29th Illinois Volunteers. The statement of Dr. Leet is corroborated by the entries on the register of the Tenth Corps Field Hospital, and by reports signed by Surgeon Barlow, 62d Ohio, and Surgeon Kitlinger, 100th New York. That of Dr. Clark is sustained by the patient, and by his attending physician Dr. G. D. Bailey, of Havana, N. Y., where the patient now resides.

**Photographed at the Army Medical Museum.**

BY ORDER OF THE SURGEON GENERAL:

GEORGE A. OTIS,

*Br't Lt. Col. and Ass't Surg. U. S. A., Curator A. M. M.*



SURGICAL PHOTOGRAPH NO. ....

*Prepared under the supervision of*  
ASSISTANT SURGEON GEORGE A. OTIS, U. S. A.  
BY ORDER OF THE SURGEON GENERAL.

WAR DEPARTMENT.  
SURGEON GENERAL'S OFFICE, ARMY MEDICAL MUSEUM

Surgeon General's Office.  
ARMY MEDICAL MUSEUM.

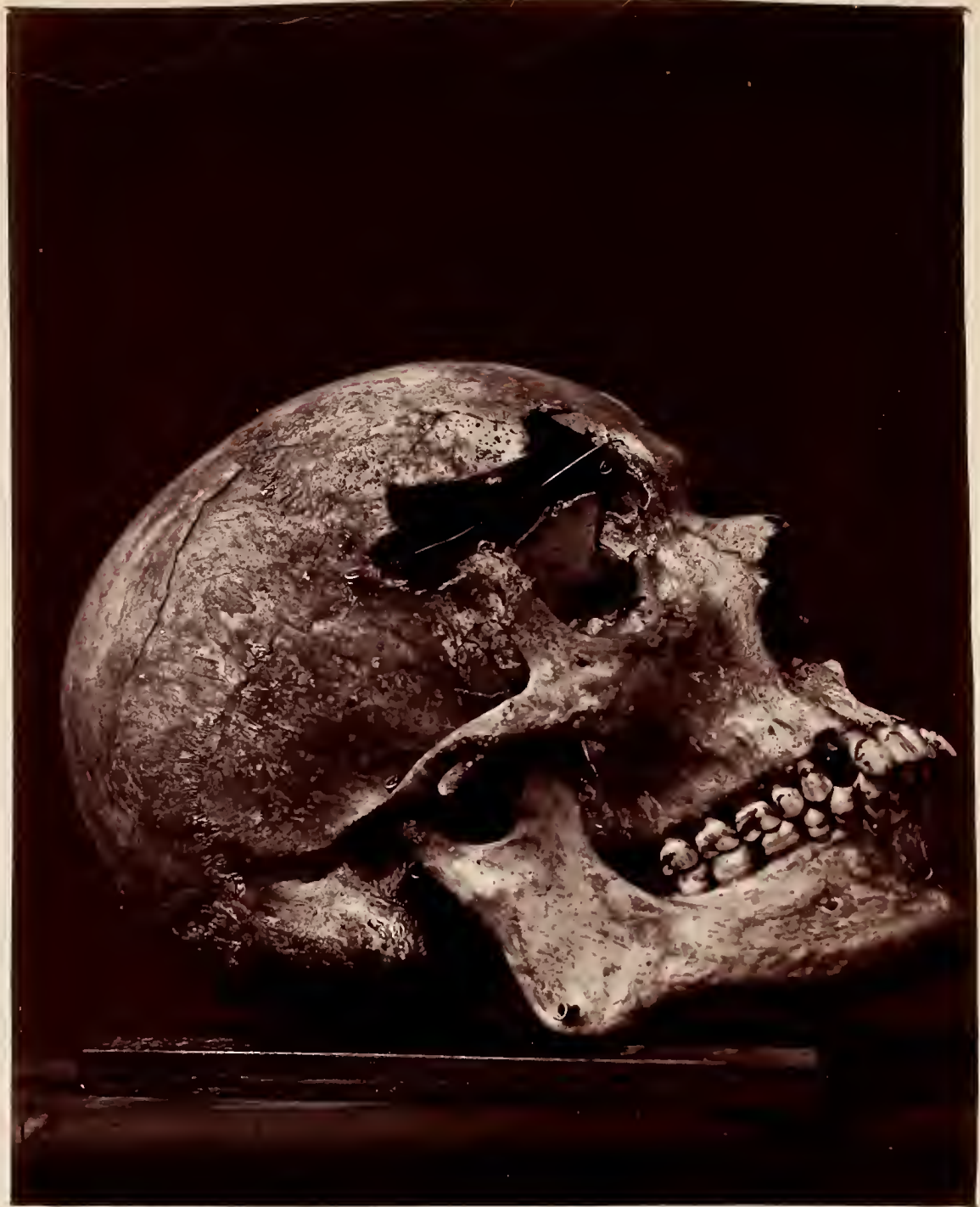
PHOTOGRAPH No. 211. *Penetrating Gunshot Fracture of the  
Cranium.*

An unknown rebel was admitted to Lincoln hospital on July 17, 1864, with a gunshot penetrating wound of skull, received at the demonstration against Fort Stevens, Washington, D. C. He died the same day. The post-mortem examination revealed a wound of the scalp two inches above the right ear, and one-half inch in diameter. The ball had entered the skull through the squamous portion of the right temporal bone, making an orifice through both tables, one and a half inches perpendicularly, and one inch horizontally. A fissure extended from the upper and anterior edge of this orifice, forwards and downwards the whole length of the squamous suture, and another at the anterior and inferior edge extended one and a half inches forwards and downwards to the tubercle. The brain in the region of the wound was pulpy, and contained a large number of spiculae of bone which had been driven in by the ball. The vessels of the left hemisphere were very much injected, and the whole brain was softened. No ball could be found in the skull. The specimen was presented to the Army Medical Museum by Acting Assistant Surgeon H. M. Dean, and is numbered 2870 of the Surgical Section.

**Photographed at the Army Medical Museum.**

BY ORDER OF THE SURGEON GENERAL:

GEORGE A. OTIS,  
*Br't Lt. Col. and Ass't Surg. U. S. A., Curator A. M. M.*



SURGICAL PHOTOGRAPH NO. . . . .

*Prepared under the supervision of*  
ASSISTANT SURGEON GEORGE A. OTIS, U. S. A.  
BY ORDER OF THE SURGEON GENERAL.

**WAR DEPARTMENT.**  
SURGEON GENERAL'S OFFICE, ARMY MEDICAL MUSEUM

Surgeon General's Office.  
ARMY MEDICAL MUSEUM.

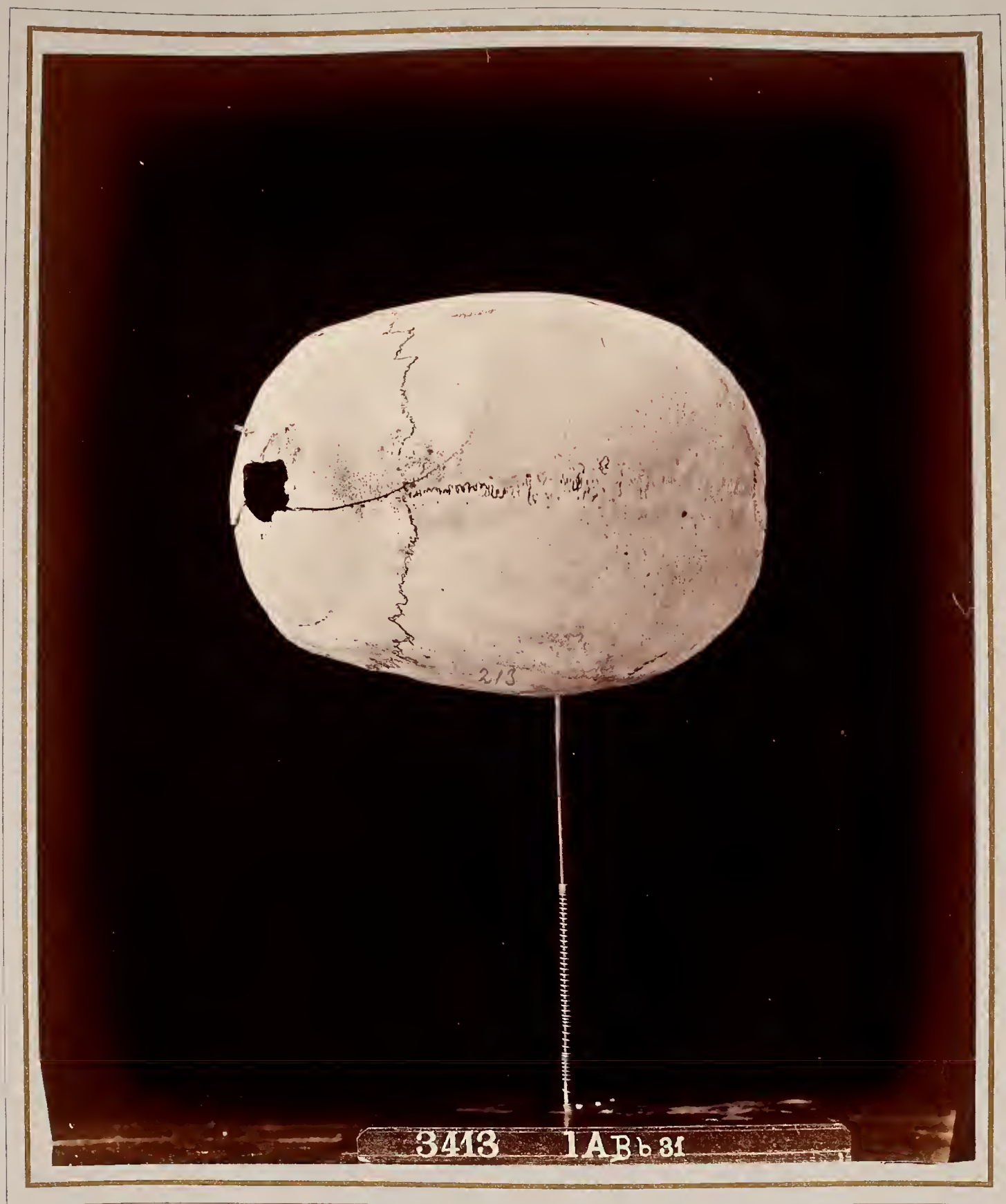PHOTOGRAPH No. 212. *Gunshot Fracture of the Cranium caused by a Musket Ball striking with great obliquity.*

Private Edward Volk, Co. D, 55th Ohio Volunteers, was wounded at the second battle of Bull Run, August 30, 1862, by a musket ball, which struck the forehead at a point half an inch above the right eyebrow, comminuting and carrying away both tables of the os frontis, to the extent of one and one-fourth by two and one-fourth inches. He remained on the battle field six days, and was then conveyed to Washington, D. C., and admitted to the Emory Hospital on the 6th of September. About one-third of the missile was found lodged against the fractured edge of the frontal bone. One-half of the plates which compose the frontal sinus were found in broken fragments piercing the brain, and were carefully removed. About a teaspoonful of brain matter escaped. There was no cerebral disturbance, and the patient was perfectly conscious. On September 8th, hernia cerebri appeared, the protrusion being about the size of a walnut. On the 19th the edges of the wound were healthy; the hernia had receded, but diarrhœa supervened, which greatly reduced the patient's strength. He died on the 25th of September. The post-mortem examination revealed a more extended fracture than was supposed to exist, reaching through the parietal to within two inches of the occipital bone. The orbital plate of the right superior maxillary was fractured and depressed, and a fissure an inch long ran down the body of the bone. The specimen was contributed by Surgeon W. Clendenin, U. S. V., and is numbered 276 of the Surgical Section.

Photographed at the Army Medical Museum.

BY ORDER OF THE SURGEON GENERAL:

GEORGE A. OTIS,  
*Br't Lt. Col. and Ass't Surg. U. S. A., Curator A. M. M.*



SURGICAL PHOTOGRAPH NO. ....

*Prepared under the supervision of*  
ASSISTANT SURGEON GEORGE A. OTIS, U. S. A.  
BY ORDER OF THE SURGEON GENERAL.

**WAR DEPARTMENT.**  
SURGEON GENERAL'S OFFICE, ARMY MEDICAL MUSEUM.

Surgeon General's Office,  
ARMY MEDICAL MUSEUM.

PHOTOGRAPH NO. 213. *Gunshot penetrating Fracture of the Frontal Bone.*

Thomas Brennen, Private, Co. I, 65th New York volunteers, aged thirty years, was struck at the battle of Cedar Creek, on October 19, 1864, by a musket ball, about the middle of the frontal bone. He was taken to Baltimore and admitted into the Jarvis U. S. A. General Hospital on the 24th, and died on the following day. For two days previous to his death, he had hemiplegia of the left side. At the autopsy twenty-four hours after death, the frontal bone was found to have been perforated near the right prominence. Two pieces of bone, each the size of a dime were driven into the dura-mater for the distance of half an inch. The brain substance near the seat of injury was very much softened. The left hemisphere was covered with clotted blood. The veins of both hemispheres were engorged with blood. A piece of the bullet was found in the third ventricle of the left hemisphere. The specimen was presented to the Army Medical Museum by Acting Assistant Surgeon B. B. Miles and is No. 3413 of the Surgical Section. It consists of the vault of the cranium, perforated in the frontal region by an opening three-fourths by one and a fourth inches. Long fissures extend from this perforation, and on its left edge is a partially fractured fragment of the inner table, an inch long and a fourth of an inch wide, depressed quarter of an inch. On the right margin of the perforation the outer table is removed leaving a sharp edge. It is probable that the ball split, a part passing out externally.

Photographed at the Army Medical Museum.

BY ORDER OF THE SURGEON GENERAL:

GEORGE A. OTIS,

*Bvt Lt. Col. and Ass't Surg. U. S. A., Curator A. M. M.*





214

SURGICAL PHOTOGRAPH NO. ....

*Prepared under the supervision of*  
ASSISTANT SURGEON GEORGE A. OTIS, U. S. A.  
BY ORDER OF THE SURGEON GENERAL.

**WAR DEPARTMENT.**  
SURGEON GENERAL'S OFFICE, ARMY MEDICAL MUSEUM.

Surgeon General's Office.  
ARMY MEDICAL MUSEUM.

PHOTOGRAPH No. 214. *Cranium Perforated by a Musket Ball.*

This cranium was presented to the Army Medical Museum by Surgeon Jerome B. Green, U. S. V., and is numbered 830 of the Surgical Section. A musket ball entered at the centre of the left branch of the coronal suture, and passed out at the posterior inferior angle of the right parietal bone, the opening of entrance being three-fourths of an inch, and that of exit one and one-fourth inches in diameter. There is a fracture of the right orbital plate of the frontal, of the squamous portion of the right temporal, and of the body of the right superior maxilla, probably by contre-coup. A fracture of the occipital bone extends from the opening of exit to the right jugular foramen. The frontal suture remains distinct, though the skull is that of a middle-aged man. The specimen is believed to have come from the 12th Army Corps hospital after the second battle of Bull Run.

Photographed at the Army Medical Museum.

BY ORDER OF THE SURGEON GENERAL:

GEORGE A. OTIS,  
*Br't Lt. Col. and Ass't Surg. U. S. A., Curator A. M. M.*



SURGICAL PHOTOGRAPH NO. ....

*Prepared under the supervision of*  
ASSISTANT SURGEON GEORGE A. OTIS, U. S. A.  
BY ORDER OF THE SURGEON GENERAL.

WAR DEPARTMENT,  
SURGEON GENERAL'S OFFICE, ARMY MEDICAL MUSEUM

Surgeon General's Office.  
ARMY MEDICAL MUSEUM.

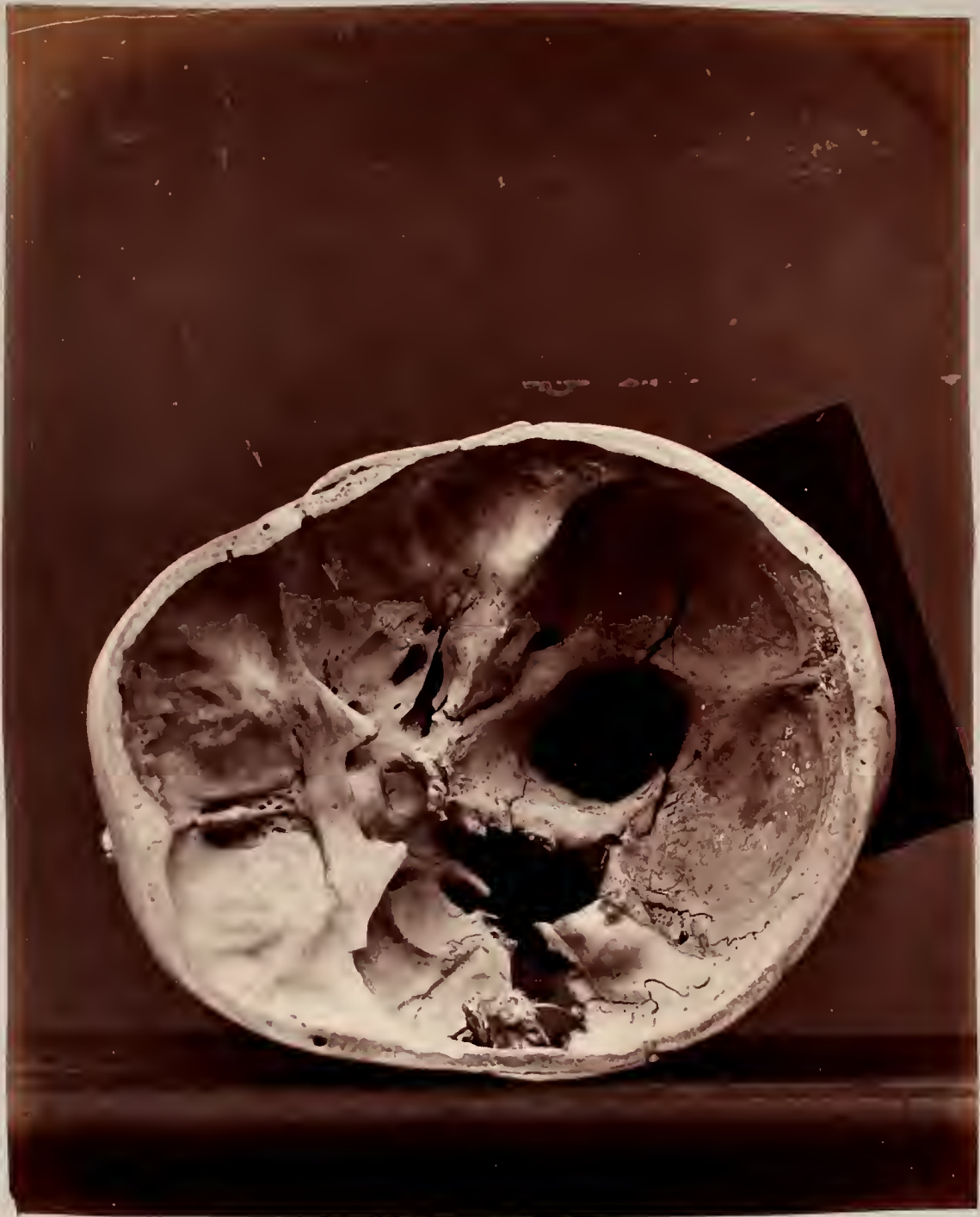PHOTOGRAPH NO. 215. *Perforation of the Cranium by a Musket Ball.*

This cranium was picked up on the first Bull Run battle-field by Dr. F. Schafhirt, and presented to the Army Medical Museum. It is numbered 3251 of the Surgical Section. It displays a fracture caused by a musket ball which, entering at the right fronto-parietal suture, and temporal ridge, and fractured the os frontis in a long fissure, which runs in front one inch above the orbits, and downwards through the greater wing of sphenoid and squamous portion of the left temporal into the mastoid process. One fissure branches off above the left orbit and downwards through the maxillary sinus. Another fissure passes posteriorly from the wound of entrance and upwards through the right to the left parietal protuberance. Another fissure downwards through the right auditory meatus has divided the petrous bone. Yet another fissure passes backwards through the upper portion of right temporal into the occiput. The ball passed out at the upper part of occipital near the inter-parietal suture.

Photographed at the Army Medical Museum.

BY ORDER OF THE SURGEON GENERAL:

GEORGE A. OTIS,  
*Be't Lt. Col. and Ass't Surg. U. S. A., Curator A. M. M.*



SURGICAL PHOTOGRAPH NO. ....

*Prepared under the supervision of*

ASSISTANT SURGEON GEORGE A. OTIS, U. S. A.  
BY ORDER OF THE SURGEON GENERAL.

WAR DEPARTMENT.

SURGEON GENERAL'S OFFICE, ARMY MEDICAL MUSEUM

Surgeon General's Office.  
ARMY MEDICAL MUSEUM.

PHOTOGRAPH No. 216. *Gunshot Fracture of Skull.*

At a post mortem examination of the body of an unknown soldier, at Lincoln Hospital, September 22, 1864, it was ascertained, that a conoidal musket ball had entered about one and a half inches above the left ear, causing a compound comminuted fracture of the squamous portion of the temporal bone. The ball was found imbedded in the lower portion of the parotid gland. The vessels of the meninges of the brain were very much injected. The middle lobe of the left hemisphere was softened to the middle corner of the lateral ventricle, which contained a small quantity of fluid, resembling blood. The specimen was contributed to the Army Medical Museum by Acting Assistant Surgeon H. M. Dean, and is numbered 3254 of the Surgical Section. It is a section of the cranium, showing penetration and fracture of the left temporal bone just above and including the meatus auditorius externus, with fracture of the occipital by contre-coup, caused by a conoidal ball, which is attached. The opening is just above the root of the zygoma and is three-fourths of an inch in diameter. The condyle of the lower jaw and the posterior half of the glenoid fossa are carried away, together with the extremity of the petrous portion of the temporal bone, the line of fracture passing through the internal meatus auditorius. From the left jugular foramen two lines of fracture pass to the foramen magnum, one in front of and the other behind the condyle. On the right side the occipital bone is traversed by a fracture which runs from the foramen magnum to the posterior angle of the right parietal.

Photographed at the Army Medical Museum.

BY ORDER OF THE SURGEON GENERAL:

GEORGE A. OTIS.

*Bvt Lt. Col. and Ass't Surg. U. S. A., Curator A. M. M.*



SURGICAL PHOTOGRAPH NO. ....

*Prepared under the supervision of*  
ASSISTANT SURGEON GEORGE A. OTIS, U. S. A.  
BY ORDER OF THE SURGEON GENERAL.

**WAR DEPARTMENT.**  
SURGEON GENERAL'S OFFICE, ARMY MEDICAL MUSEUM.

# Surgeon General's Office.

## ARMY MEDICAL MUSEUM.

### PHOTOGRAPH No. 217. *Successful Intermediate Excision of the Right Knee-Joint.*

Captain Charles Knowlton, 10th Louisiana Regiment, of Ewell's Corps, aged twenty-six years was wounded at Mine Run, Virginia, November 27, 1863, by a conoidal musket ball, which grooved the outer condyle of the right femur, barely touched the cartilage, opened the synovial sac, was deflected, and lodged near the upper edge of the patella whence it was removed, on the field, through an incision, after the wounded man had walked half a mile to the rear leaning on the shoulder of one of his men. He was then transported over rough roads in an ambulance to the nearest railway station, and conveyed to Richmond and entered General Hospital No. 4, two days after receiving the injury. His condition on admission was good. There appeared to have been no hæmorrhage. The movements of the knee-joint were perfect. Moist dressings, absolute rest, and saline aperients were ordered. On December 2d a serous or synovial discharge from the wound was observed. This became slightly puriform on the following day. Still there was no mark of inflammatory reaction. On December 8th there was much pain in the joint and the discharge was increased. His pulse rose to 104. On the 9th the joint was excessively inflamed and the pulse was 128. Surgeon James B. Read, P. A. C. S., in consultation with Surgeons C. B. Gibson, and M. Michel decided that excision of the joint was expedient. The operation was performed by Surgeon Read. An elliptical incision with its concavity upwards was made to extend from one condyle to the other passing below the patella, and dividing its ligament. The joint was then laid open, and an inch and a half of the condyles of the femur, and an inch of the tibia were sawn off. The patella was also removed. No ligatures were required. The section of the femur was made obliquely downwards and backwards; the section of the tibia was the reverse of this, so that when the extremities were approximated the limb was slightly flexed. The synovial sac was reddened and contained a turbid flocculent fluid. The sawn ends of the bones were then wired together. The limb was then placed in a long well padded fracture box. After a few days a long bracketed splint was substituted for the fracture box. He had a liberal stimulating diet of eggs, oysters, and beef-tea, with half an ounce of brandy every two hours. The patient was restless and irritable, and on December 16th, and again on the 20th, had venous hæmorrhage to the extent of a few ounces, the bleeding being arrested on both occasions by the use of persulphate of iron. There was tumefaction about the joint and burrowing of pus, until Acting Assistant Surgeon Howell D. Thomas suggested a suspension of the limb by Smith's anterior splint. By January 3d the internal half of the horse-shoe incision had closed. The patient enjoyed an excellent appetite, which was appeased by venison, turkey, partridges, and other hearty food and a pint of porter daily. By the middle of February there was only a small fistulous orifice remaining of the wound, which discharged a thin, sero-purulent matter. A starch bandage was now applied, with an aperture over the unhealed portion of the wound. All the wires had been removed at this date except one. In March the patient sat up daily and attempted to walk on crutches. In April he was discharged from the hospital; his limb was supported by a leathern splint. There was still slight motion between the femur and tibia; but the ligamentous union appeared quite firm. He subsequently went to the West Indies. At Nassau, Dr. Hunt, of New Orleans, removed the starch bandage and found the consolidation was very firm. In a few months Captain Knowlton laid aside his crutches, and walked very satisfactorily. He returned to Louisiana in 1866. He was able not only to walk almost as well as ever, and to dance even the round dances. His address as a purser on one of the Pacific mail steamers having been discovered, Surgeon Charles McCormick, U. S. Army, at San Francisco, examined his limb, December 17, 1868, and had made the negative from which this photograph is printed. There was no evidence of disease about the cicatrix; The muscular development of the limb was good; and the inability to flex it at the knee was the only inconvenience suffered, a result as gratifying as it is unusual.

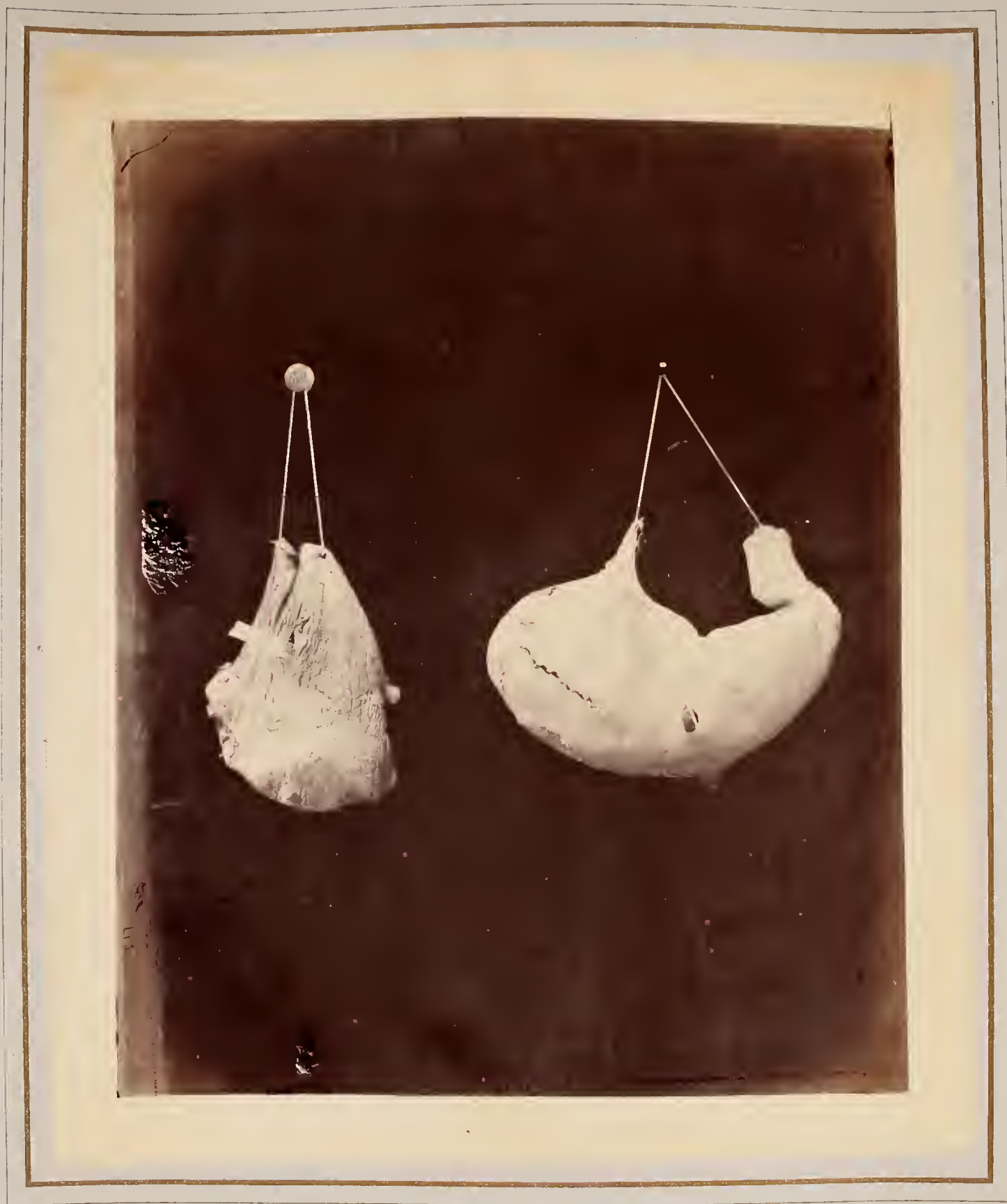Photographed at the Army Medical Museum.

BY ORDER OF THE SURGEON GENERAL:

GEORGE A. OTIS,

*Br't Lt. Col. and Ass't Surg. U. S. A., Curator A. M. M.*





SURGICAL PHOTOGRAPH NO. ....

*Prepared under the supervision of*  
ASSISTANT SURGEON GEORGE A. OTIS, U. S. A.  
BY ORDER OF THE SURGEON GENERAL.

**WAR DEPARTMENT.**  
SURGEON GENERAL'S OFFICE, ARMY MEDICAL MUSEUM.

Surgeon General's Office.  
ARMY MEDICAL MUSEUM.

PHOTOGRAPH No. 218. *Perforation of Stomach by a Conoidal Musket Ball.*

Private John Brown, Co. I, 9th Minnesota Volunteers, aged twenty-eight years, was wounded in front of Nashville, Tennessee, December 16, 1864, by a conoidal musket ball, which penetrated the left chest at the cartilaginous junction of the eighth and ninth ribs, three inches below the nipple. On the night of the same day he was admitted to Hospital No. 8, Nashville. The shock of injury was very great, and he suffered intensely from sharp pain in the chest and abdomen. There was, also, paralysis of motion and of sensation in the left lower extremity. Expectant treatment was used, but the patient soon collapsed, and died at 8.30, P. M., on December 17, 1864. At an autopsy, twenty-two hours after death, pleuritic adhesions were found; the capacity of left lung was much diminished; the abdominal cavity showed evidences of intense peritonitis, and the viscera were softened and of a dark green color. The missile had passed downwards, inwards and backwards, and piercing the diaphragm near its anterior border, leaving an opening two inches in length through which a portion of omentum had escaped into the lower cavity of thorax, perforated the splenic end of the stomach, leaving an interval of three inches between the openings; thence, it passed through the transverse colon, and fecal matter, with a large amount of escaped blood, was found in the abdominal cavity; it then struck the left anterior side of the fourth lumbar vertebra, grooving deeply its left border, passed through the spinal cord to its left surface, fractured the left horizontal and spinous processes of the third lumbar vertebra, and was found immediately to the right of the second lumbar vertebra, underlying the integument and fascia of that region, very much changed from its original shape. The injured vertebræ are shown in Specimen 3748, Army Medical Museum.

Photographed at the Army Medical Museum.

BY ORDER OF THE SURGEON GENERAL:

GEORGE A. OTIS,  
*Ass't Surg. U. S. A., Curator A. M. M.*



**SURGICAL PHOTOGRAPH NO.** .....

*Prepared under the supervision of*  
ASSISTANT SURGEON GEORGE A. OTIS, U. S. A.  
BY ORDER OF THE SURGEON GENERAL.

**WAR DEPARTMENT.**  
SURGEON GENERAL'S OFFICE, ARMY MEDICAL MUSEUM

Surgeon General's Office.  
ARMY MEDICAL MUSEUM.

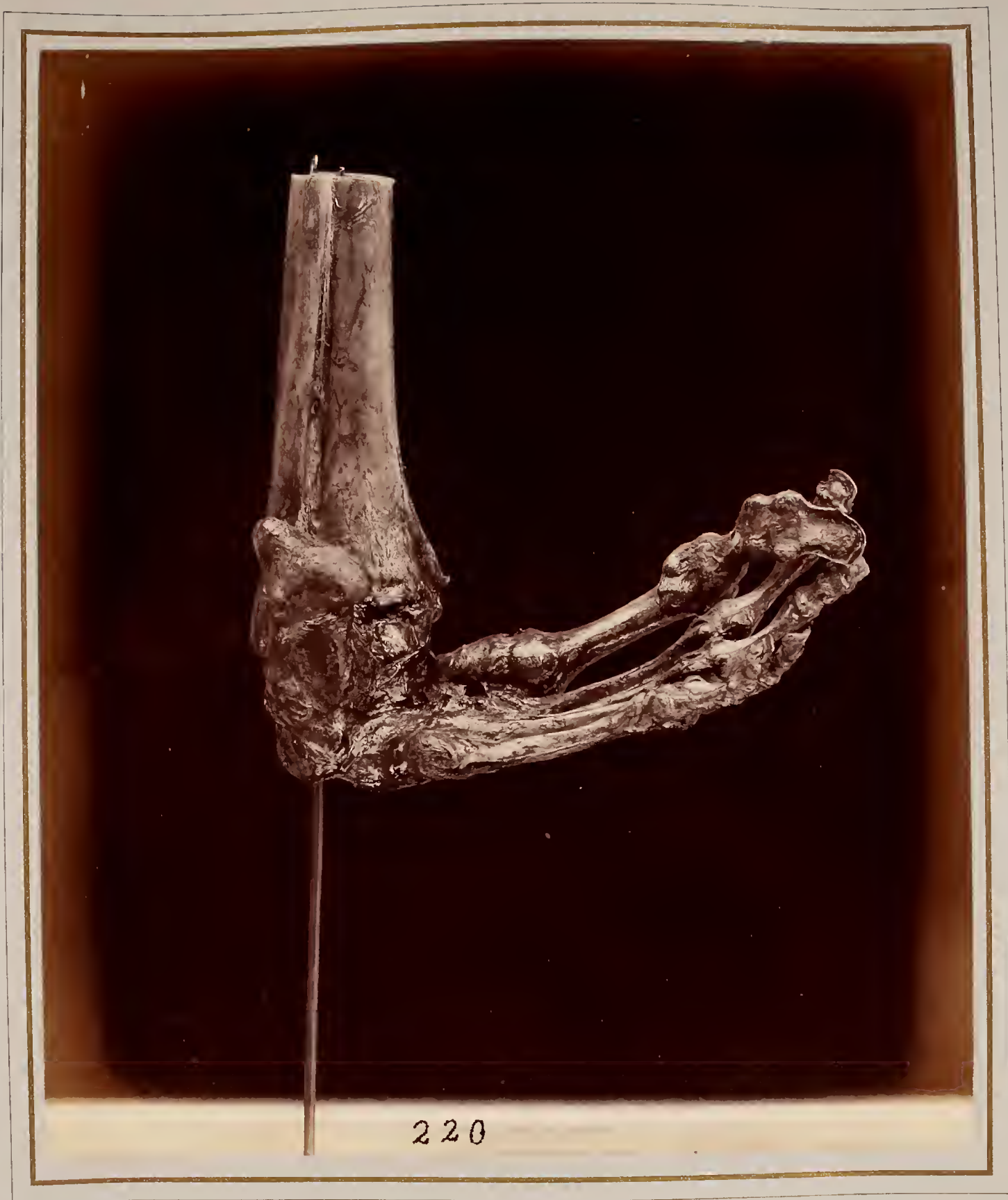
PHOTOGRAPH No. 219. *Hypertrophied Prostate Gland and Bladder, containing twelve large Uric Acid Calculi.*

This specimen was taken from a private patient, aged sixty-seven, a native of Frederick, Maryland, who died August 3, 1857. Besides the large conerctions, the bladder contained numerous hemp-seed calculi, many of which were discharged during life. In 1849 more than three hundred were discharged through the fenestra of a very large catheter. The lobes of the prostate are much enlarged. On the right and middle lobes are several ulcers. The walls of the bladder are much thickened. The specimen measures as follows: from fundus to membranous portion of urethra, six inches; across fundus and body of bladder, in which the calculi are contained, four and one-eighth inches; from external wall of fundus to top of middle lobe, two inches and seven-sixteenths; thickness of walls of bladder, seven-eighths of an inch. The width of the left lobe of enlarged prostate is one inch; that of the right lobe two inches. The width of the divided and degenerated prostate is four inches and ten-sixteenths. An analysis of the calculi by Dr. B. F. Craig shows that they consist almost entirely of uric acid. The specimen with the history was contributed by Dr. Robert K. Stone, of Washington.

Photographed at the Army Medical Museum.

BY ORDER OF THE SURGEON GENERAL:

GEORGE A. OTIS,  
*Ass't Surg. U. S. A., Curator A. M. M.*



SURGICAL PHOTOGRAPH NO. ....

*Prepared under the supervision of*  
ASSISTANT SURGEON GEORGE A. OTIS, U. S. A.  
BY ORDER OF THE SURGEON GENERAL.

**WAR DEPARTMENT.**  
SURGEON GENERAL'S OFFICE, ARMY MEDICAL MUSEUM.

Surgeon General's Office.  
ARMY MEDICAL MUSEUM.

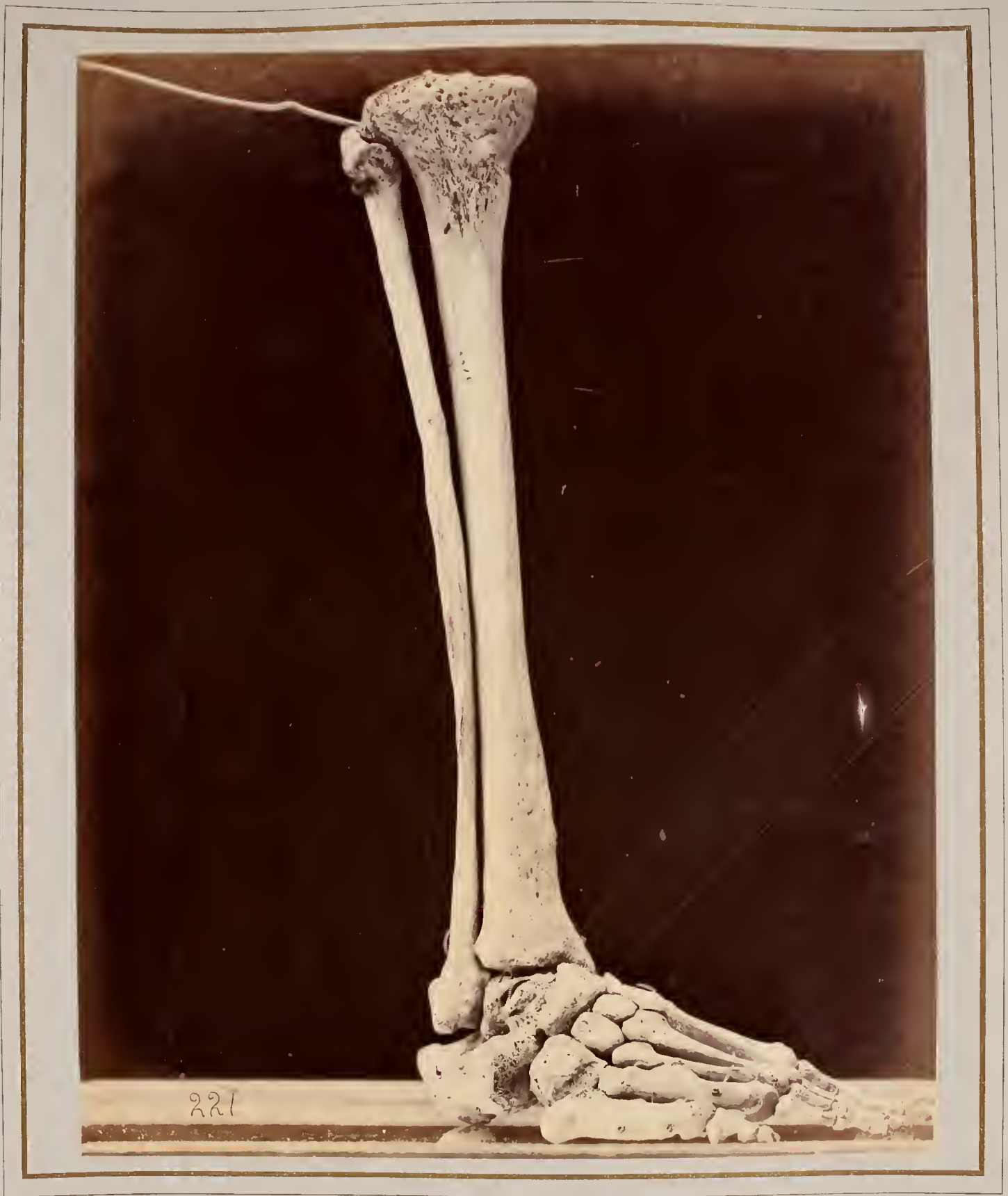PHOTOGRAPH No. 220. *Ligamentous Preparation of the Bones of the Left Foot and Lower Portions of the Leg Bones, from a Case of Confirmed Talipes Varus.*

This specimen, No. 852, Army Medical Museum, was taken from a Freedman, who died of syphilis on November 25, 1866, at the Freedman's Hospital in Washington. It was contributed, with the history, by Hospital Steward A. M. Squier, U. S. A. The foot is completely inverted, and the os calcis, which is small, is nearly parallel with the shafts of the leg bones, and presents an irregular, knotted appearance. The patient walked chiefly upon the anterior surface of the calcaneum and the astragalus and dorsal surfaces of the other tarsal bones. The metatarsals are unusually slender, and the great toe overlaps the two adjoining ones.

Photographed at the Army Medical Museum.

BY ORDER OF THE SURGEON GENERAL:

GEORGE A. OTIS,  
*Ass't Surg. U. S. A., Curator A. M. M.*



**SURGICAL PHOTOGRAPH NO.** .....  
*Prepared under the supervision of*  
ASSISTANT SURGEON GEORGE A. OTIS, U. S. A.  
BY ORDER OF THE SURGEON GENERAL.

**WAR DEPARTMENT.**  
SURGEON GENERAL'S OFFICE, ARMY MEDICAL MUSEUM.

Surgeon General's Office.  
ARMY MEDICAL MUSEUM.

PHOTOGRAPH No. 221.

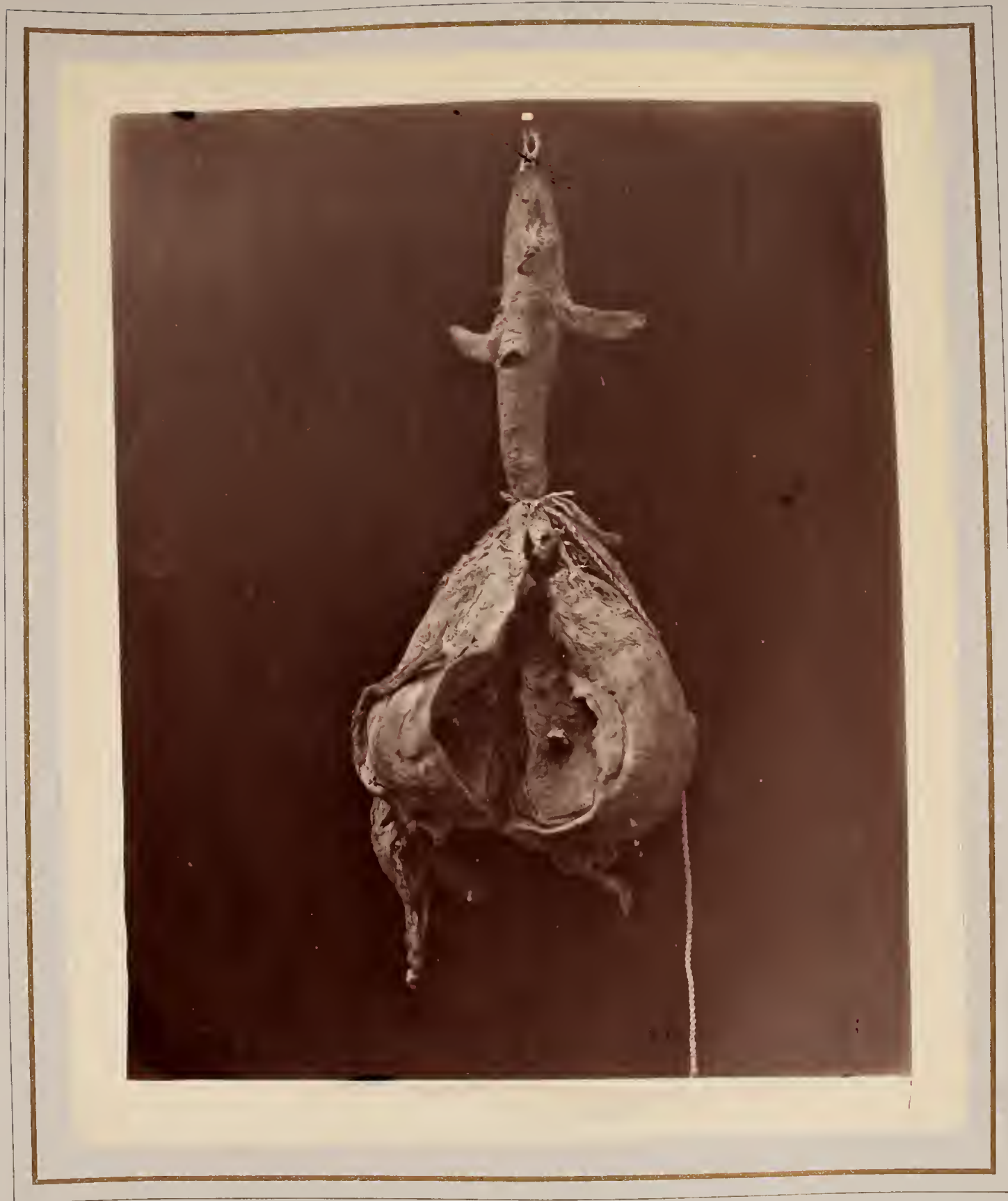This is a representation of Specimen 5188 of the Surgical Section of the Army Medical Museum, showing the bones of the right leg and foot, with a luxation forward of the astragalus. The fibula exhibits an extraordinary concavity in its external middle third. The specimen is from the Van Wyck private collection, and was received with the Gibson Collection.

**Photographed at the Army Medical Museum.**

**BY ORDER OF THE SURGEON GENERAL:**

**GEORGE A. OTIS,**  
*Ass't Surg. U. S. A., Curator A. M. M.*





SURGICAL PHOTOGRAPH NO. ....

*Prepared under the supervision of*  
ASSISTANT SURGEON GEORGE A. OTIS, U. S. A.  
BY ORDER OF THE SURGEON GENERAL.

WAR DEPARTMENT.  
SURGEON GENERAL'S OFFICE, ARMY MEDICAL MUSEUM.

# Surgeon General's Office.

## ARMY MEDICAL MUSEUM.

PHOTOGRAPH No. 222. *Ligation of the Abdominal Aorta for Aneurism.*

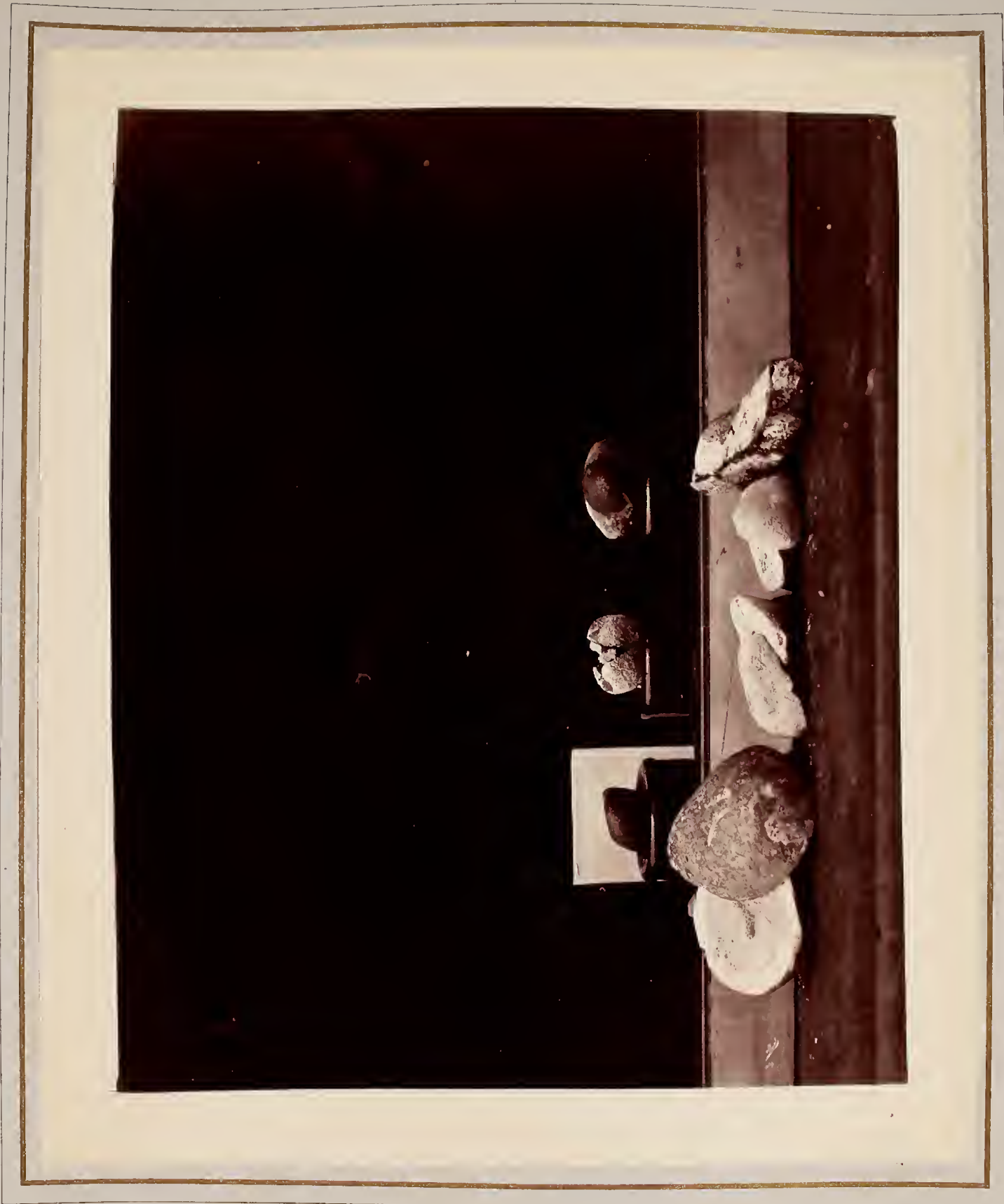
William Fancy, a negro of thirty years, a wood chopper, was admitted to the Howard Grove Hospital, at Richmond, Virginia, March 20, 1868. He stated that a week before while pursuing his ordinary avocation he felt something give way in the lower part of his abdomen, a sensation followed by nausea and great pain. Dr. Hunter McGuire examined, and found in the left iliac and hypogastric regions an aneurismal tumor the size of a goose egg. No pulsation could be discovered in the left femoral; but no change in the temperature or size of the left leg was observed. His general health was good. The patient said that the tumor gradually increased in size and was daily growing worse. Rest in bed, with digitalis, iron, acetate of lead and opiates seemed to alleviate the pain and to diminish the size of the tumor; but the relief was but temporary. On March 26th, compression of the aorta was resorted to; but had to be discontinued because of the tenderness of the tumor. On March 30th, at 1, P. M., Dr. McGuire, after consultation with Professors Joynes, Wellford and others, determined to cut down and to ligate the common iliac above the aneurism. When the aneurism was exposed, it was found to involve the whole of the common iliac, and the aorta near its bifurcation. The sac was very thin. Dr. McGuire now determined to tie the aorta, when the sac suddenly ruptured, although it had been handled with the utmost delicacy, and a profuse discharge of blood took place. The aorta was instantly compressed by the finger an inch above the tumor, and surrounded by an assistant with a ligature and tied. About a pint of blood was removed from the cavity of the abdomen. The lips of the wound were brought together. Sutures and bandages were applied. A stimulating enema was given. The patient was put to bed and the lower extremities were surrounded by warm applications. In a few moments the effects of chloroform passed off, and slight reaction took place. He complained much of numbness of the lower extremities. The temperature of the axilla never rose above 96. He died half an hour after midnight, eleven and a half hours after the operation. At the autopsy, the ligature was found to embrace the aorta at the origin of the inferior mesentery and included the left ureter. The rent in the sac was just over the bifurcation of the aorta. A careful report of the case is published by Prof. H. McGuire in the *American Journal of the Medical Sciences*, Vol. LVI, p. 415, October, 1868. The pathological specimen was contributed to the Army Medical Museum by Dr. McGuire, and is numbered 5256, Section I.

**Photographed at the Army Medical Museum.**

BY ORDER OF THE SURGEON GENERAL:

GEORGE A. OTIS,

*Bo't Lt. Col. and Ass't Surg. U. S. A., Curator A. M. M.*



SURGICAL PHOTOGRAPH NO. ....

*Prepared under the supervision of*

ASSISTANT SURGEON GEORGE A. OTIS, U. S. A  
BY ORDER OF THE SURGEON GENERAL.

WAR DEPARTMENT.

SURGEON GENERAL'S OFFICE, ARMY MEDICAL MUSEUM.

# Surgeon General's Office.

## ARMY MEDICAL MUSEUM.

PHOTOGRAPH No. 223. *Vesical Concretions resulting from Gunshot Injuries.*

This photograph represents a series of seven specimens of foreign bodies removed from the bladder, all of which were directly or indirectly the result of gunshot injuries. These cases will be fully described in the forthcoming Surgical History of the War. A simple memorandum is here given. The left hand figure of the upper row, (Specimen 5019) is a round leaden bullet slightly encrusted, removed from the bladder of a South Carolinian soldier in 1865, by Dr. F. T. Miles, of Charleston. The man was struck at the first battle of Bull Run, July, 1861, above the pubes. The wound healed kindly and he returned to duty, and fought through the war, and never had any dysuria until the march to Appomattox Court House in April, 1865, when suddenly he had extreme pain in the bladder, bloody urine, and other symptoms of a foreign body in the bladder. A few weeks subsequently, the encrusted ball was successfully removed by lateral lithotomy. The middle figure of the upper row, (Specimen 4712) represents half of a urinary calculus formed after a gunshot wound of the fundus of the bladder, with inspissated mucous probably as its nucleus, and consisting of mixed phosphates. It was successfully removed by lateral lithotomy by Prof. J. J. Chisolm. The right hand figure, (Specimen 5520) represents an iron shrapnel ball encrusted with uric acid and triple phosphates, which was successfully removed by Dr. A. N. Dougherty, at the New Jersey Home for Disabled Soldiers, in August, 1868. The man was wounded in April, 1865. The operation done by Dr. Dougherty (formerly Medical Director of the Second Army Corps) was by an external incision as for bilateral lithotomy, with a deep incision as in the lateral method. The operation was very successful. The concretion weighed one ounce and twenty-three grains avoirdupois. The left hand figure in the lower row, (Specimen 5041) represents a large phosphatic calculus sawn in half. Its nucleus is a portion of the pubic bone, which was driven into the bladder by a musket ball, which passed out through the rectum. Three and a half years after the reception of the injury, this calculus was removed by lateral lithotomy by Prof. Hunter McGuire, who has given an account of the case in the *Richmond Medical Journal*, of April, 1868. At the time of its removal, the calculus weighed two and a quarter ounces. With a good lens, the Haversian canal in the bone which forms the nucleus can be readily made out. The two middle figures in the lower row, (Specimen 2567) represent two uric acid calculi found *post mortem* in the case of a soldier who was shot through the bladder at the second battle of Bull Run, by a musket ball, which entered above the pubes and passed downwards and backwards through the coccyx. The specimen was contributed by Surgeon D. W. Bliss, U. S. Vols. The right hand lower figure, (Specimen 88) represents one view of a fragment of a grenade removed from the bladder by Surgeon J. F. Randolph, U. S. Army. The case is recorded in the Surgical Report in Circular No. 6, Surgeon General's Office, 1865, p. 29.

Photographed at the Army Medical Museum.

BY ORDER OF THE SURGEON GENERAL:

GEORGE A. OTIS,

*Br't Lt. Col. and Ass't Surg. U. S. A., Curator A. M. M.*



SURGICAL PHOTOGRAPH NO. ....

*Prepared under the supervision of*

ASSISTANT SURGEON GEORGE A. OTIS, U. S. A.  
BY ORDER OF THE SURGEON GENERAL.

**WAR DEPARTMENT.**

SURGEON GENERAL'S OFFICE, ARMY MEDICAL MUSEUM

Surgeon General's Office.  
—♦—  
ARMY MEDICAL MUSEUM.  
—♦—

PHOTOGRAPH NO. 224. *Four Urinary Calculi in the collection of the Army Medical Museum.*

All the figures in this group are much reduced. That on the left represents a very large mulberry calculus. Its length is two and a quarter inches, breadth one and seven-eighths inches, thickness one and five-sixteenths inches, and weight 2.48 ounces Troy. It was removed by lateral lithotomy by Dr. N. S. Lincoln, of Washington, who has published a description of the case in the *Richmond and Louisville Medical Journal*. The next figure, (Specimen 5058) represents a calculus presented to the late Dr. William Gibson, in 1843, by Dr. Stout, of Easton, Pennsylvania. The nucleus is a large darning needle. (See Gibson's *Surgery*, 7th Edition, Vol. II, p. 230.) It was removed from the bladder of a negro girl. The next figure, (Specimen 4833) represents a phosphatic calculus sawn asunder, and weighing 27.054 grammes. It was obtained by exchange from the National Medical College, at Washington. The nucleus was a watermelon seed. It was removed by lithotomy from the bladder of a nasty fellow. The right hand figure, (Specimen 4866) represents a very large ovoid phosphatic calculus, weighing 159.53 grammes. It was successfully removed from the bladder of a man from Ohio, by Surgeon J. G. F. Holston, U. S. Vols., by lateral lithotomy. Its surface is quite smooth, and its composition unusually homogeneous. It is rarely that so large a concretion is removed by lithotomy without being crushed and removed in fragments. The long diameter of this calculus is two and three-eighths inches, and the smallest diameter is two inches. There are larger vesical calculi in the collection, but they were removed after death.

**Photographed at the Army Medical Museum.**

BY ORDER OF THE SURGEON GENERAL:

GEORGE A. OTIS,

*Br't Lt. Col. and Ass't Surg. U. S. A., Curator A. M. M.*



SURGICAL PHOTOGRAPH NO. ....

*Prepared under the supervision of*  
ASSISTANT SURGEON GEORGE A. OTIS, U. S. A.  
BY ORDER OF THE SURGEON GENERAL.

**WAR DEPARTMENT.**  
SURGEON GENERAL'S OFFICE, ARMY MEDICAL MUSEUM

# Surgeon General's Office.

## ARMY MEDICAL MUSEUM.

PHOTOGRAPH No. 225. *Transverse Fracture of the Femur in the Middle Third by an unknown Missile.*

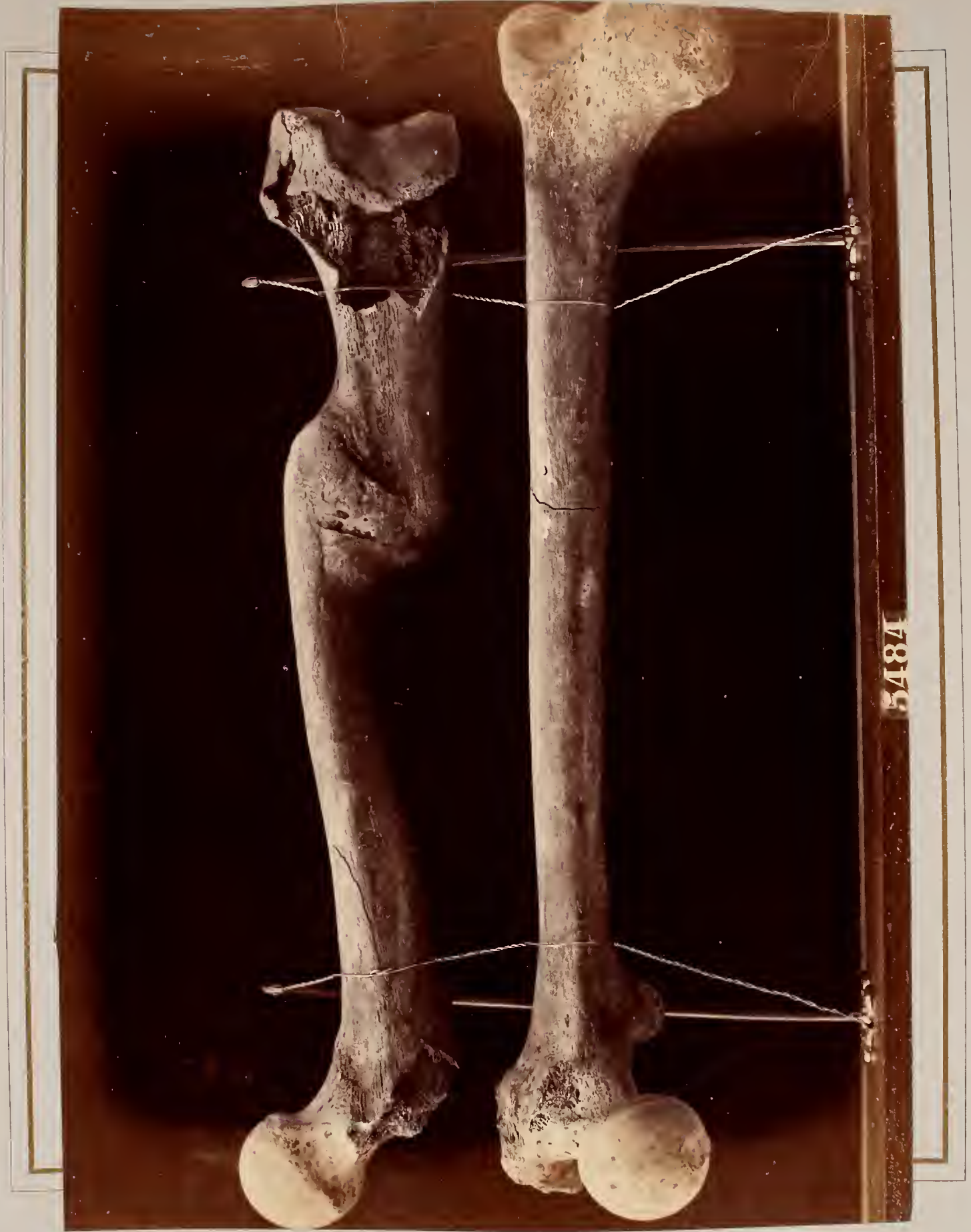Elijah Brown, a colored civilian, aged fifty years, and by occupation a farm laborer, was injured August 15, 1864, at City Point, by the explosion of ordnance stores. An unknown missile produced a compound fracture of the femur in the middle third, leaving a wound similar to that made by a conoidal ball. He was sent to Philadelphia, and, on August 20th, was admitted to Satterlee Hospital. No foreign body could be detected in the wound. The limb was shortened some two and a half or three inches; the thigh was much swelled; and there was a profuse discharge from the wound, and a commencing bed sore over the sacrum. The patient's bowels were loose, and he was thin and debilitated, but, withal, was cheerful and had a good appetite. An angular wire splint, thought not to meet the required indications, was removed, and a straight wooden one, with the counter-extending band in the perineum, was substituted. Fifteen drop doses of tincture of iron were also administered three times a day. This treatment continued until August 27th, when the splint was removed, and extension made by means of weights suspended from leg by adhesive strips, husk bags being placed along either side. This arrangement, along with the straight board splint, was extremely inconvenient, and could not be kept in proper order. The bed sore had become the source of great discomfort, the discharge being profuse and exhausting. Simple dressings and expectant treatment were used. On September 1st, all appliances were removed from the leg. The patient was much reduced by suppuration from the wound and from the bed sore. He was extremely restless, and there were no signs of union of the fragments. A profuse diarrhœa withstanding all treatment now set in, and continued until the patient's death, which occurred at 8, A. M., on September 12, 1864. The specimen, showing considerable exfoliation near the two ends of the fragments, was contributed, with the history, by Acting Assistant Surgeon A. L. Eakin.

**Photographed at the Army Medical Museum.**

**BY ORDER OF THE SURGEON GENERAL:**

**GEORGE A. OTIS,**  
*Ass't Surg. U. S. A., Curator A. M. M.*





SURGICAL PHOTOGRAPH NO. 5484

*Prepared under the supervision of*  
ASSISTANT SURGEON GEORGE A. OTIS, U. S. A.  
BY ORDER OF THE SURGEON GENERAL.

WAR DEPARTMENT.  
SURGEON GENERAL'S OFFICE, ARMY MEDICAL MUSEUM

Surgeon General's Office.  
ARMY MEDICAL MUSEUM.

PHOTOGRAPH No. 226. *United Simple Fracture of the Right Femur of a Mound Builder.*

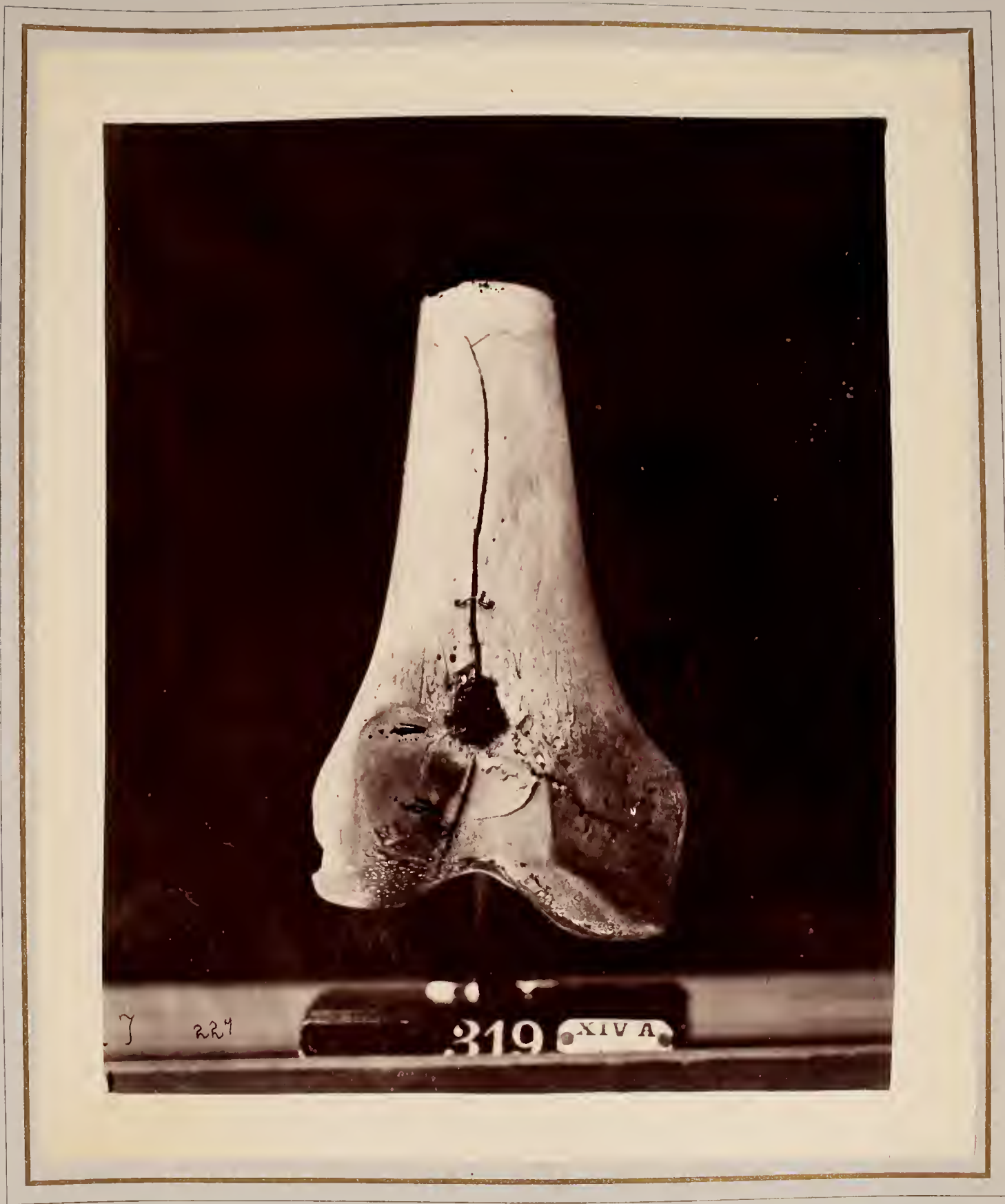In 1868, Acting Assistant Surgeon A. J. Comfort made a minute and painstaking exploration of several tumuli in the vicinity of Fort Wadsworth, Dakota Territory. He was fortunate enough to obtain from these mounds, which, from the large size of the trees upon their summits, were evidently of great antiquity, about forty human skeletons, more or less complete, which he sent to the Army Medical Museum. They furnish several examples of fracture of the long bones. In the united fracture of the long bone of the femur which is exhibited in the photograph, there was less than two inches shortening, the length being fifteen and seven-eighths inches, while the companion femur, which shows a kind of post-mortem fracture, is seventeen and three-fourths inches in length. The angular deformity is slight, and the result is not discreditable to prehistoric surgery. The bones are yellow, and very fragile. A full account of Dr. Comfort's interesting researches, together with other archæological reports, is in process of compilation at this Office for publication in the next volume of the Smithsonian Contributions to Knowledge.

Photographed at the Army Medical Museum.

BY ORDER OF THE SURGEON GENERAL:

GEORGE A. OTIS,

*Bvt Lt. Col. and Ass't Surg. U. S. A., Curator A. M. M.*



SURGICAL PHOTOGRAPH NO. ....

*Prepared under the supervision of*  
ASSISTANT SURGEON GEORGE A. OTIS, U. S. A.  
BY ORDER OF THE SURGEON GENERAL.

**WAR DEPARTMENT,**  
SURGEON GENERAL'S OFFICE, ARMY MEDICAL MUSEUM.

# Surgeon General's Office.

## ARMY MEDICAL MUSEUM.

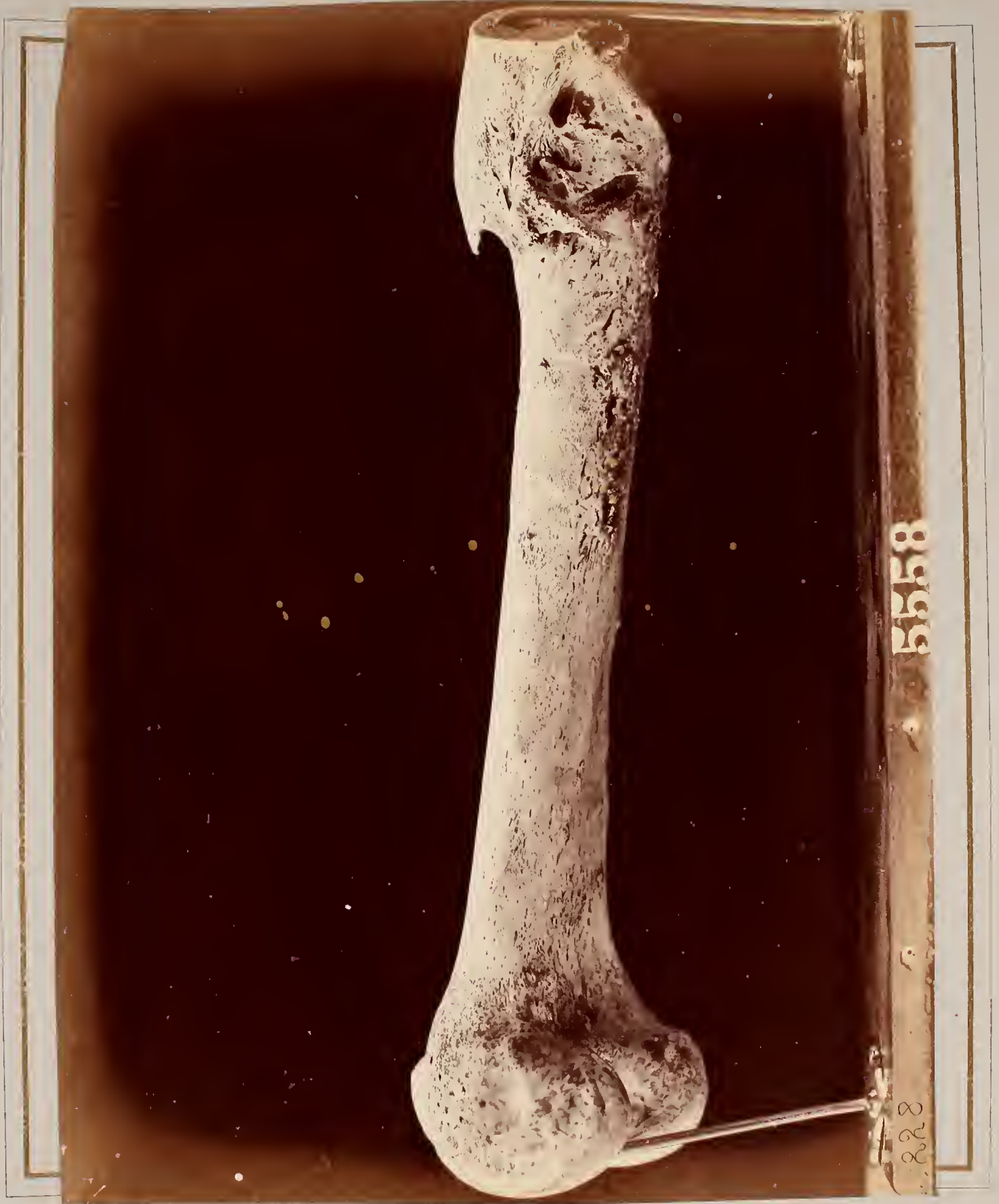PHOTOGRAPH No. 227. *Distal Extremity of the Right Femur showing a Perforating and Longitudinal Fracture, with Comminution, by a Spherical Musket-shot.*

Private Reuben Donelly, Co. A, 21st Ohio Volunteer, was wounded at Bull Run, August 30, 1862, by a spherical musket-shot, which entered the right thigh just above the patella, and, passing directly through the limb from front to rear, divided the condyles, split the shaft upward several inches, and comminuted the bone at the intercondyloid notch. He was admitted to the King Street Hospital at Alexandria on September 3, 1862, and, two days afterward, Surgeon J. E. Summers, U. S. A., amputated the thigh at the junction of the lower and middle third by the antero-posterior flap operation. The case progressed favorably until October 3d, (a cold, rainy day) when the patient had a severe chill, which recurred on the following afternoon. Tonics and stimulants were freely administered, notwithstanding which he gradually sank; absorption of the new granulations took place; the edges of the flaps retracting, left the bone exposed; osteomyelitis occurred; and there was extreme emaciation, with great prostration, and inability to take or retain nourishment or stimulants, resulting in the death of the patient October 20, 1862. The specimen and history were contributed by Acting Assistant Surgeon Thomas O. Barker, U. S. A.

Photographed at the Army Medical Museum.

BY ORDER OF THE SURGEON GENERAL:

GEORGE A. OTIS,  
*Ass't Surg. U. S. A., Curator A. M. M.*



SURGICAL PHOTOGRAPH NO. ....

*Prepared under the supervision of*  
ASSISTANT SURGEON GEORGE A. OTIS, U. S. A.  
BY ORDER OF THE SURGEON GENERAL.

WAR DEPARTMENT.  
SURGEON GENERAL'S OFFICE, ARMY MEDICAL MUSEUM.

# Surgeon General's Office.

## ARMY MEDICAL MUSEUM.

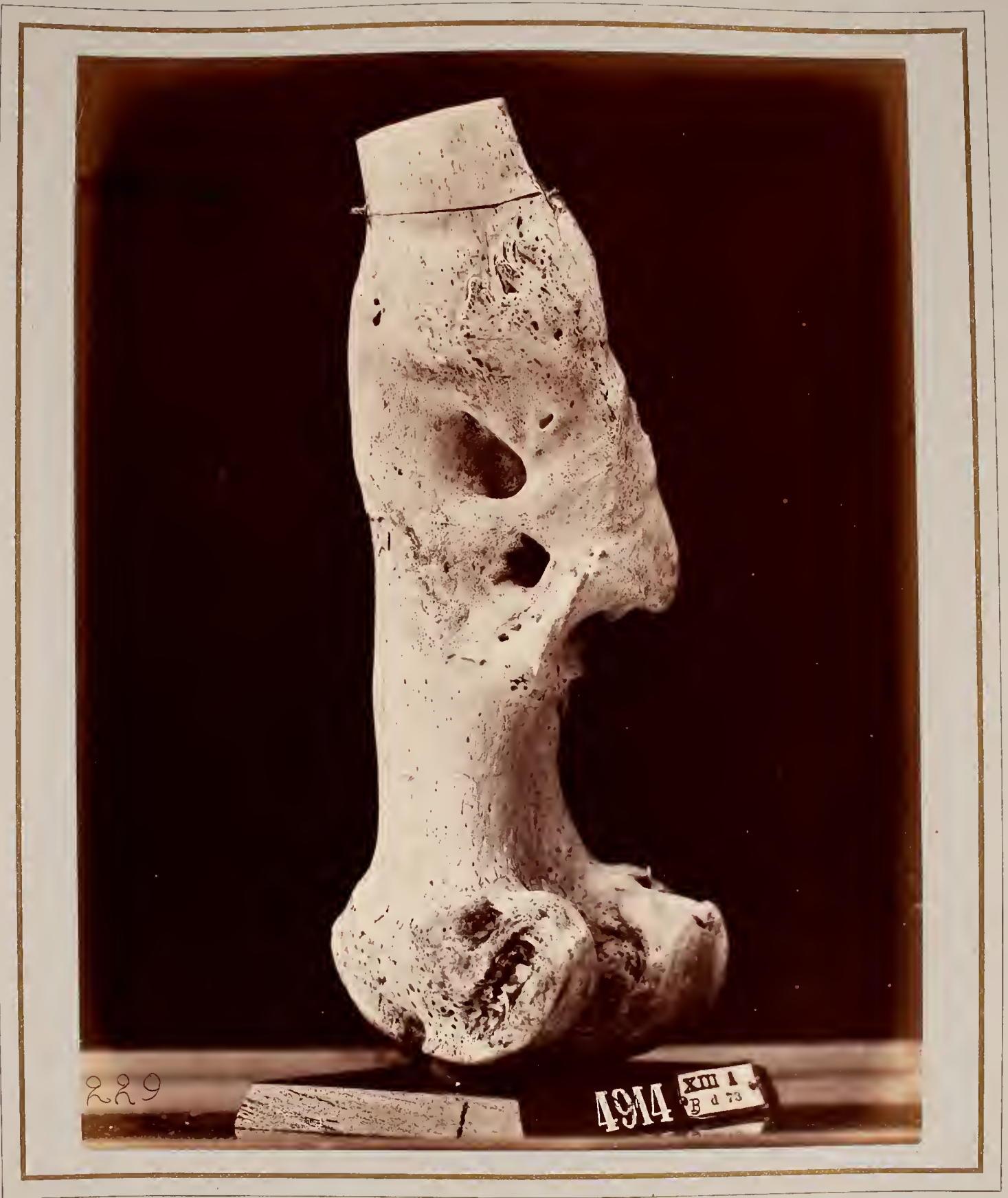PHOTOGRAPH No. 228. *Amputated Portion of the Right Femur, showing United Fracture, with a Fragment of Lead imbedded in the Callus.*

Private Jesse M. Jones, Co. K, 21st Indiana Volunteers, aged twenty-nine years, was wounded at Baton Rouge, Louisiana, August 5, 1862, by a musket ball, which fractured the right femur at the junction of middle and upper third. He was taken to the regimental hospital the night after, remained a day, and was thence sent by a transport steamer to New Orleans, the limb meanwhile being supported by bandages and pillows. On arrival, August 7th, he was admitted to the St. James Hospital, where a long splint was applied, seventeen days after the reception of the wound. The patient was discharged the service April 15, 1863, since when, up to January, 1869, he suffered much pain from frequent exfoliations and abscesses. At the latter date, he entered Providence Hospital at Washington; and on the 23d, Doctor D. W. Bliss, late Surgeon, U. S. V., amputated the thigh in the upper third, and afterwards contributed the pathological specimen to the Army Medical Museum. It is No. 5558 of the Surgical Section, and shows great deformity and exfoliations on posterior aspect. On March 9, 1869, he visited the Museum, recovered, and his photograph was taken to accompany the specimen. (A. M. M. Card Photographs, Vol. 1, page 27.)

**Photographed at the Army Medical Museum.**

**BY ORDER OF THE SURGEON GENERAL:**

**GEORGE A. OTIS,**  
*Ass't Surg. U. S. A., Curator A. M. M.*



SURGICAL PHOTOGRAPH NO. ....

*Prepared under the supervision of*  
ASSISTANT SURGEON GEORGE A. OTIS, U. S. A.  
BY ORDER OF THE SURGEON GENERAL.

WAR DEPARTMENT.  
SURGEON GENERAL'S OFFICE, ARMY MEDICAL MUSEUM.



Surgeon General's Office.  
ARMY MEDICAL MUSEUM.

PHOTOGRAPH No. 229. *Lower Half of the Left Femur Successfully Amputated.*

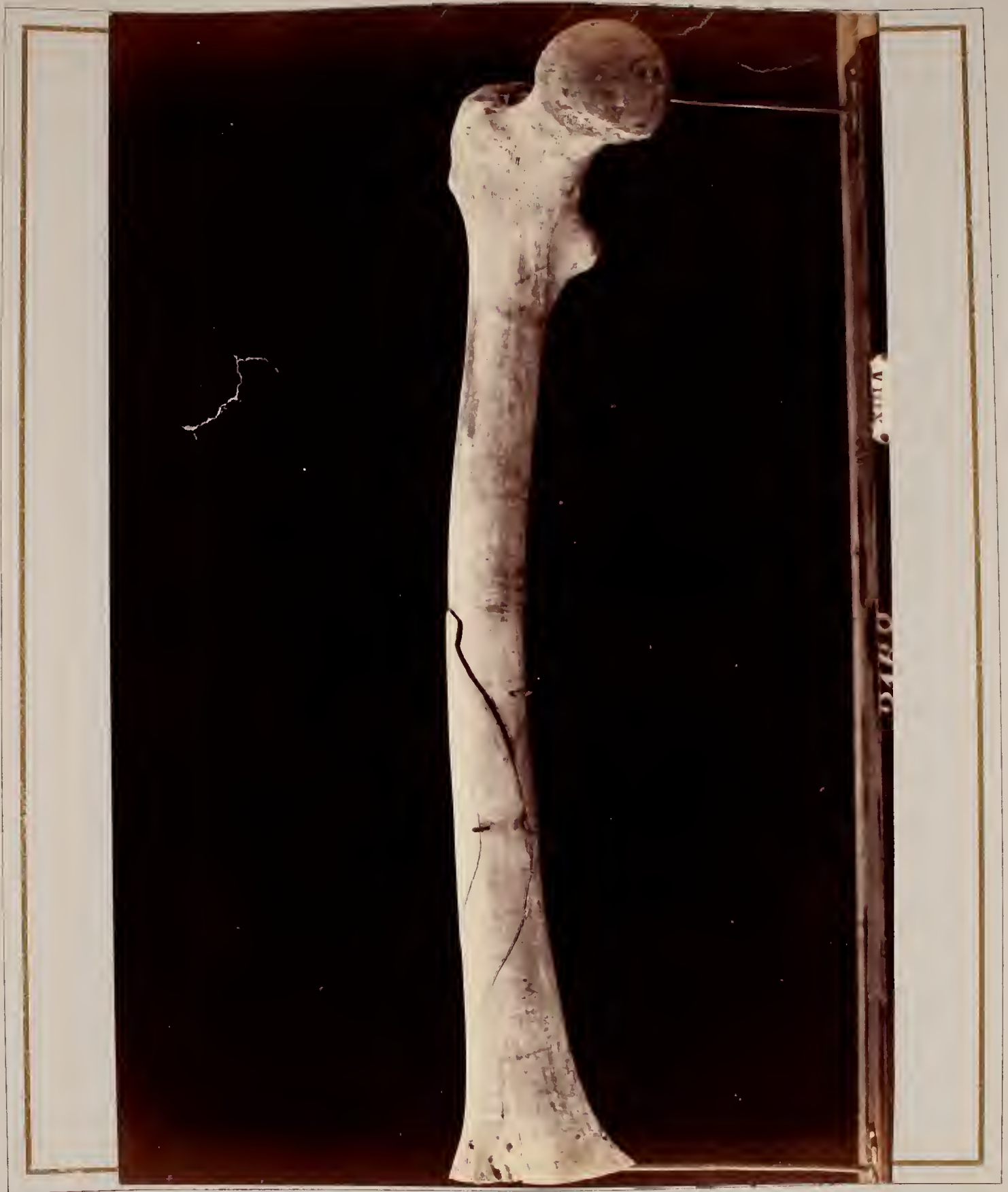Private C. H. Bowen, Co. A, 27th Indiana Volunteers, had his left femur fractured by a musket ball, at the battle of Antietam, on September 17, 1862. He was admitted to Hospital No. 1, at Frederick, Maryland, where Buek's apparatus was applied. Nine months subsequently, he was removed to Baltimore. There were numerous abscesses, and the patient underwent two operations for the removal of necrosed bone. On September 7, 1863, he was discharged the service, with the limb greatly deformed. He received a pension, and was employed in the Interior Department. Owing to recurrence of abscesses he was admitted to Providence Hospital in the autumn of 1867, and on November 11th, the limb was amputated in the middle third by Dr. D. W. Bliss. The wound healed well, and a photograph was taken at the Army Medical Museum on January 9, 1868, at which time the stump was firm and healthy. The specimen, with the history, was contributed by the operator. The fragments are considerably overlapped, having undergone unusual disturbance, and the amount of callus exceeds what is necessary for complete union.

Photographed at the Army Medical Museum.

BY ORDER OF THE SURGEON GENERAL:

GEORGE A. OTIS,  
*Ass't Surg. U. S. A., Curator A. M. M.*





SURGICAL PHOTOGRAPH NO. ....

*Prepared under the supervision of*  
ASSISTANT SURGEON GEORGE A. OTIS, U. S. A.  
BY ORDER OF THE SURGEON GENERAL.

**WAR DEPARTMENT.**  
SURGEON GENERAL'S OFFICE, ARMY MEDICAL MUSEUM

Surgeon General's Office.  
ARMY MEDICAL MUSEUM.

PHOTOGRAPH No. 230. *The Greater Portion of the Right Femur, exhibiting an oblique Fracture, from a Conoidal Musket Ball impinging against the Inner Aspect, a little below the Middle.*

Private James H. Wager, Co. H. 125th New York Volunteers, aged twenty-one years, was wounded at the battle of Hatcher's Run, on April 2, 1865, by a conoidal musket ball which passing upward and backward and producing two wounds, fractured the right femur at the junction of the lower and middle third. He was sent to the field hospital of the 2d Corps at City Point, Virginia, and, on the 4th, was transferred to the Douglas Hospital at Washington, where he arrived, on the 5th, in a very low condition, being anæmic and debilitated, with rapid pulse, flushed cheeks, and ieterus. The knee joint was also much swollen. The following day he was etherized and the wound thoroughly examined by Acting Assistant Surgeon C. Carvallo, who extracted pieces of bullet from each wound. Stimulants and concentrated nourishment were freely administered without effect, and the patient died from exhaustion on April 10, 1865. At the autopsy, twelve hours after death, decomposition was rapidly setting in; the thoracic and abdominal viscera appeared healthy; the fractured femur was disarticulated and sawn longitudinally, the medullary substance appearing inflamed, red and hardened. The case is interesting from the number of pieces into which the bullet was split; viz., one which made its exit, two taken from the wounds, and one found near the bone at the *post mortem*, making four in all. The pathological specimen was contributed by Assistant Surgeon W. F. Norris, U. S. A., and is No. 3168 of the Surgical Section.

Photographed at the Army Medical Museum.

BY ORDER OF THE SURGEON GENERAL:

GEORGE A. OTIS,  
*Ass't Surg. U. S. A., Curator A. M. M.*



SURGICAL PHOTOGRAPH NO. ....

*Prepared under the supervision of*  
ASSISTANT SURGEON GEORGE A. OTIS, U. S. A.  
BY ORDER OF THE SURGEON GENERAL.

WAR DEPARTMENT.  
SURGEON GENERAL'S OFFICE, ARMY MEDICAL MUSEUM

Surgeon General's Office.  
ARMY MEDICAL MUSEUM.

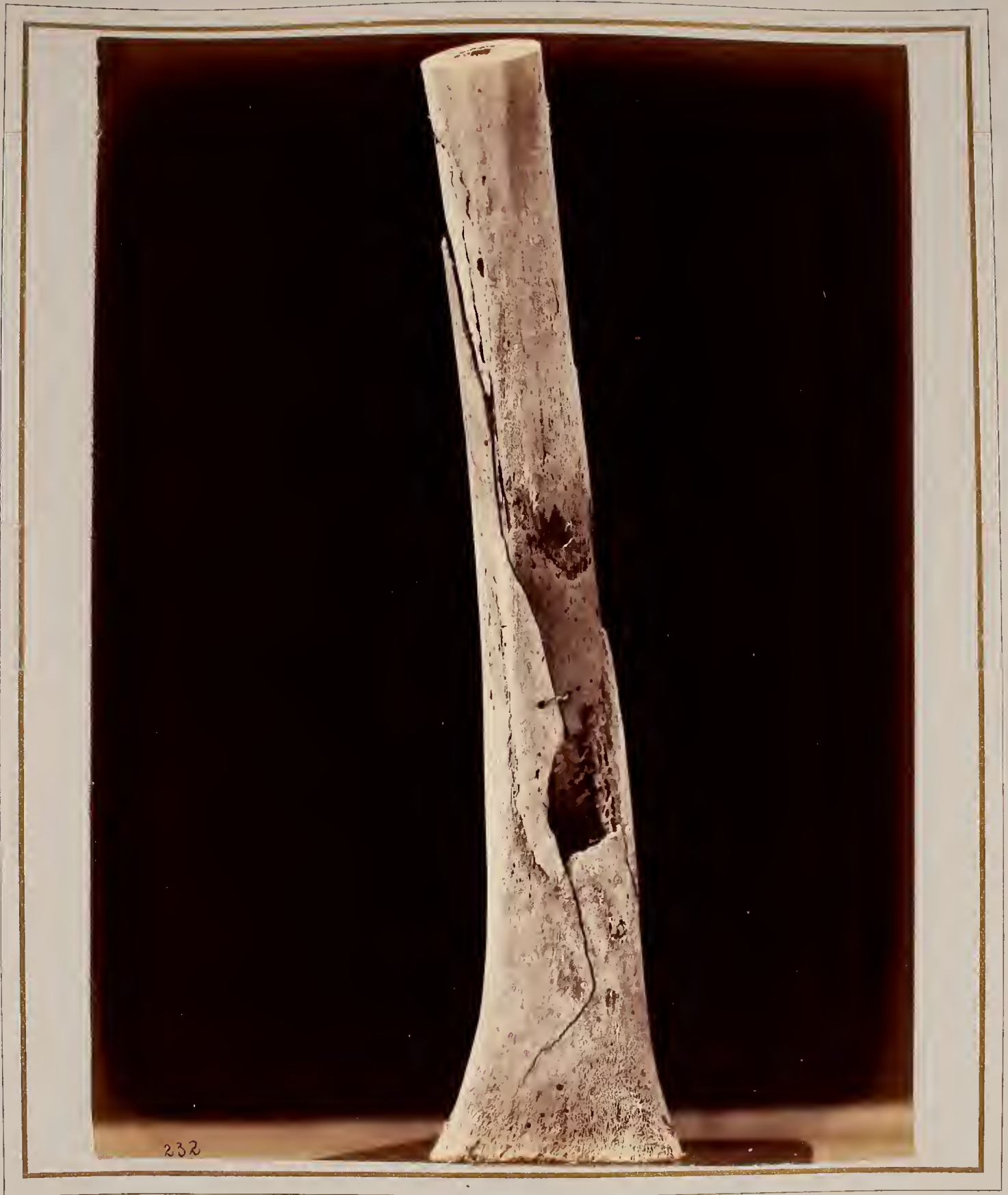PHOTOGRAPH No. 231. *Lower Half of Right Femur, exhibiting an Osteoplastic Operation and a Secondary Amputation.*

Private Grey Y. Barrett, Co. F, 5th New Hampshire Volunteers, aged twenty years, was wounded at Fredericksburg on December 13, 1862, by a musket ball, which entered the outer condyle, and, escaping posteriorly in the middle of the lower third of thigh, left the bone much comminuted at its exit. He was admitted to the hospital of the First Division, Ninth Corps, where, on the 16th, Assistant Surgeon J. W. S. Gouley, U. S. A., amputated the femur a short distance above the wound of entrance, the patella being included in the anterior flap; the line of section not having escaped the wound, another third of an inch was removed; the femoral surface of the patella was then sawn off, and the two cut surfaces of the bone were brought in apposition. The laminated portion of the femur, however, was fractured half an inch above this point, and fissures extended two inches further. On the sixth day sloughing commenced; on the eighth, signs of gangrene were noticed; and on the ninth, December 25th, Surgeon J. P. Prince, 36th Massachusetts Volunteers, amputated the femur in the middle third, on account of the burrowing of pus, for secondary hæmorrhage from the propliteal. No plastic deposit could be observed immediately after the operation. On the next day he was transferred to Washington, and admitted to the Douglas Hospital, where he died on December 27, 1862. The pathological specimen, which is No. 536, Surgical Section, was contributed, with the history, by Surgeon J. P. Prince, 36th Massachusetts Volunteers.

Photographed at the Army Medical Museum.

BY ORDER OF THE SURGEON GENERAL:

GEORGE A. OTIS,  
*Ass't Surg. U. S. A., Curator A. M. M.*



SURGICAL PHOTOGRAPH NO. . . . .

*Prepared under the supervision of*  
ASSISTANT SURGEON GEORGE A. OTIS, U. S. A.  
BY ORDER OF THE SURGEON GENERAL.

**WAR DEPARTMENT,**  
SURGEON GENERAL'S OFFICE, ARMY MEDICAL MUSEUM.

Surgeon General's Office.  
ARMY MEDICAL MUSEUM.

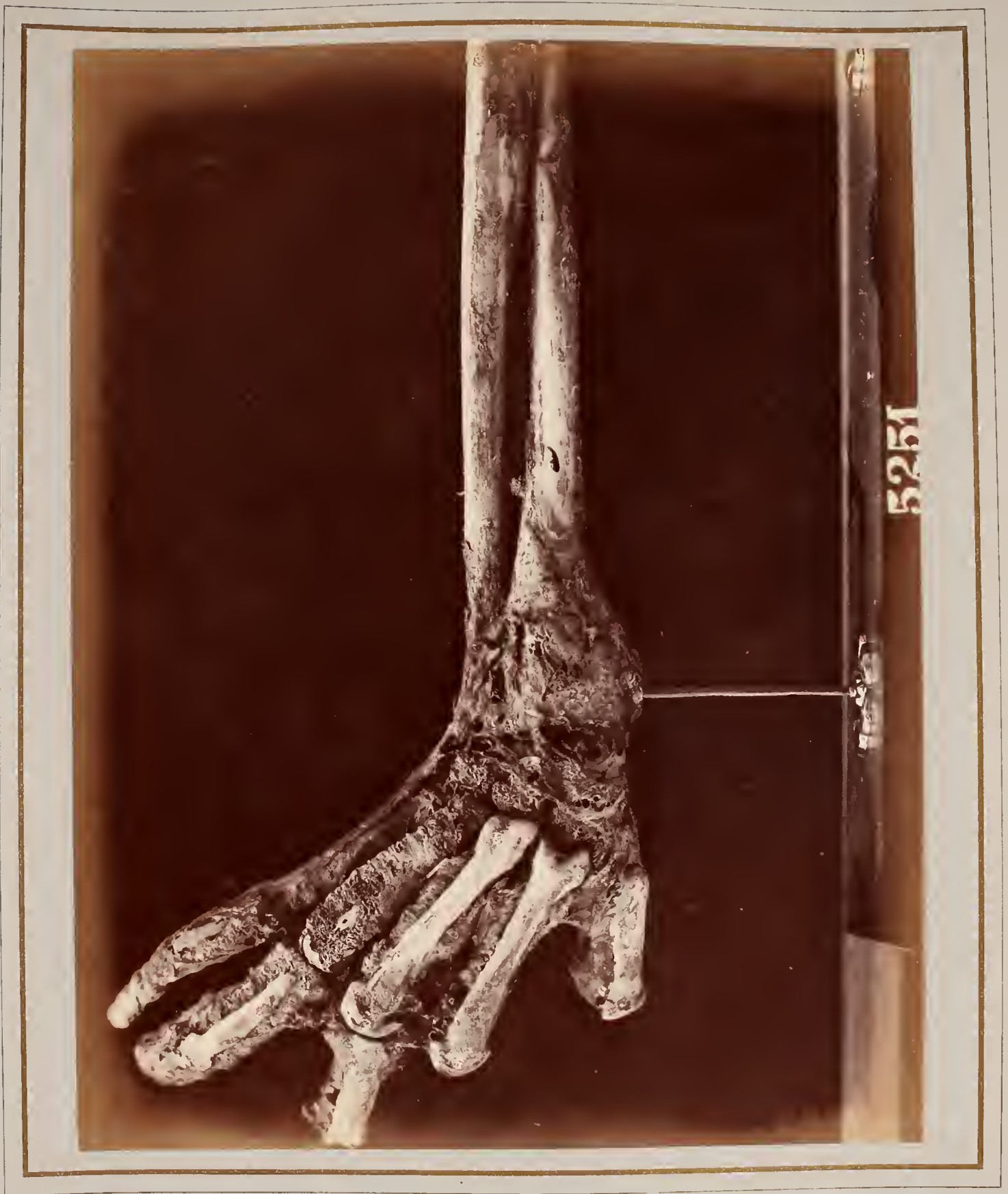PHOTOGRAPH No. 232. *Shaft of the Left Femur, exhibiting  
Comminution in the Middle Third, with Extensive Longitudinal  
Fracture, produced by a Conoidal Musket Ball.*

Private Thomas Holmes, Co. D, 1st Michigan Sharpshooters, aged twenty years, was wounded at Spottsylvania Court House on May 10, 1864, by a conoidal musket ball, which entered the inner aspect of the left thigh, one inch above the patella, and, passing upwards and outwards, made its exit on the outer surface of thigh at the middle third. He was carried nine miles in an ambulance to the general hospital at Fredericksburg, and was, afterwards, admitted to the Armory Square Hospital at Washington on May 26, 1864. No apparatus had been applied to the limb. Shortly after admission chloroform was administered, but, after a consultation, it was decided that he could not bear amputation. The injured limb was then placed in a fracture box, and strong stimulants were given. The patient lingered until June 10, 1864, when he died from exhaustion. The pathological specimen, which is superficially necrosed, was contributed, with history, to the Army Medical Museum by Surgeon D. W. Bliss, U. S. V., and is numbered 2486, in the Surgical Section.

Photographed at the Army Medical Museum.

BY ORDER OF THE SURGEON GENERAL:

GEORGE A. OTIS,  
*Ass't Surg. U. S. A., Curator A. M. M.*



SURGICAL PHOTOGRAPH NO. ....

*Prepared under the supervision of*  
ASSISTANT SURGEON GEORGE A. OTIS, U. S. A.  
BY ORDER OF THE SURGEON GENERAL.

WAR DEPARTMENT,  
SURGEON GENERAL'S OFFICE, ARMY MEDICAL MUSEUM.

Surgeon General's Office.  
—••—  
ARMY MEDICAL MUSEUM.  
—••—

PHOTOGRAPH No. 233. *Reproduction of the Metacarpals and  
Phalanges after Necrosis.*

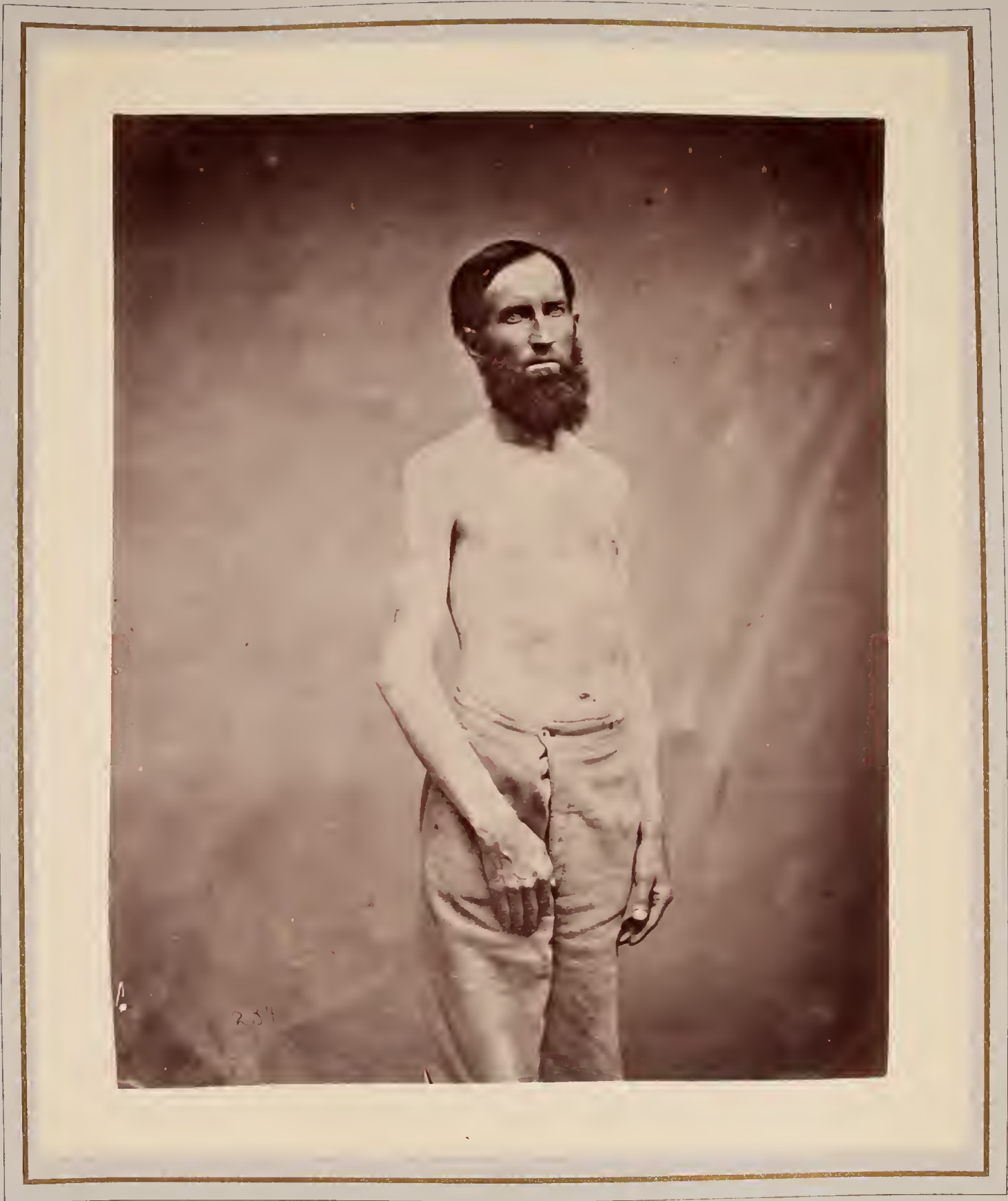
The specimen is from the Gibson Collection, and is numbered 5251 of  
the Surgical Section, Army Medical Museum.

**Photographed at the Army Medical Museum.**

**BY ORDER OF THE SURGEON GENERAL:**

**GEORGE A. OTIS,**  
*Ass't Surg. U. S. A., Curator A. M. M.*





SURGICAL PHOTOGRAPH NO. ....

*Prepared under the supervision of*  
ASSISTANT SURGEON GEORGE A. OTIS, U. S. A.  
BY ORDER OF THE SURGEON GENERAL.

WAR DEPARTMENT.  
SURGEON GENERAL'S OFFICE, ARMY MEDICAL MUSEUM.

# Surgeon General's Office.

## ARMY MEDICAL MUSEUM.

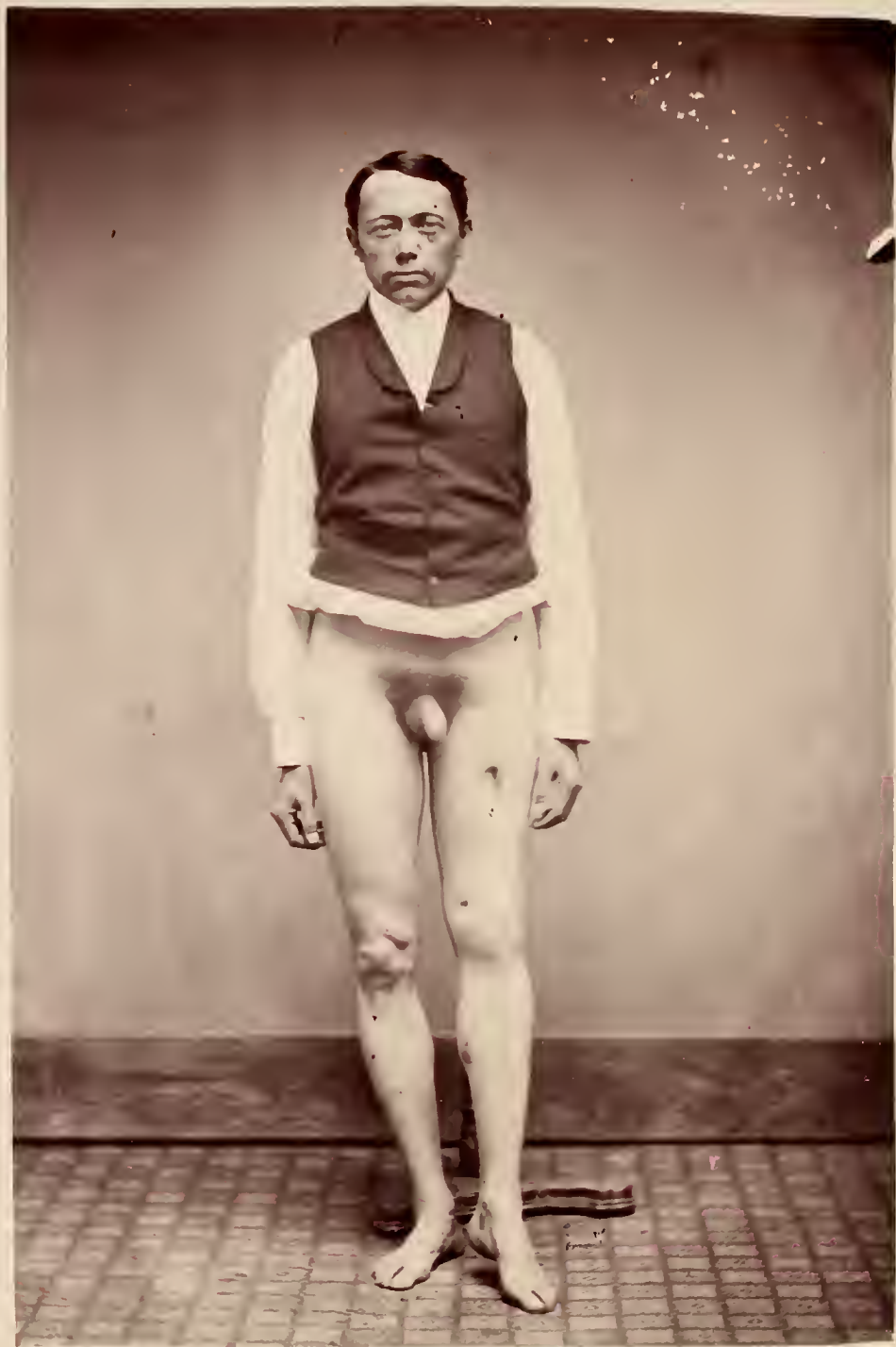PHOTOGRAPH No. 234. *Excision of Five Inches of the Shaft of the Right Humerus.*

Private Herman L. Maynard, Co. C, 17th New Hampshire Volunteers, aged thirty-one years, was wounded at Olustee, Florida, on February 20, 1864, by a conoidal musket ball, which entered the right arm at the middle and outer aspect, and fractured the humerus at the upper third. On the 25th, he was admitted from Jacksonville, Florida, to the hospital at Hilton Head, South Carolina, where the arm was unsuccessfully treated with splints. On March 9th, being etherized, a portion of the bone, about five inches long, was excised. The arm was much swollen, very painful, and the soft parts were much lacerated. His constitutional condition was good. Water dressings and a concave coaptation splint were applied. In about two months, there was sufficient deposit of bone to render the arm firm without shortening. On June 25th, the patient was admitted to the Central Park Hospital, New York City. The wound was in a sloughing condition, and numerous fragments of exfoliated bone were removed. He was discharged the service on September 7, 1864, at which date the wound was reported healed and the arm firm. On September 14, 1864, Pension Examiner J. Clough reported the wound discharging profusely, and, every few days, pieces of bone were extracted. The arm was ankylosed, and he rated his disability total and doubtful. On August 12, 1869, a photograph was taken, which was contributed to the Army Medical Museum by Dr. J. O. Webster, of the National Asylum for Discharged Volunteer Soldiers at Augusta, Maine. The limb was almost as strong as its fellow, but it had shortened nearly two inches, and the wound of exit had not healed.

Printed at the Army Medical Museum.

BY ORDER OF THE SURGEON GENERAL:

GEORGE A. OTIS,  
*Ass't Surg. U. S. A., Curator A. M. M.*



**SURGICAL PHOTOGRAPH NO. . . . .**

*Prepared under the supervision of*  
ASSISTANT SURGEON GEORGE A. OTIS, U. S. A.  
BY ORDER OF THE SURGEON GENERAL.

**WAR DEPARTMENT.**  
SURGEON GENERAL'S OFFICE, ARMY MEDICAL MUSEUM.

# Surgeon General's Office.

## ARMY MEDICAL MUSEUM.

PHOTOGRAPH No. 235. *Partial Recovery from a Compound Fracture of the Left Thigh in the Upper Third, caused by a Conoidal Musket Ball.*

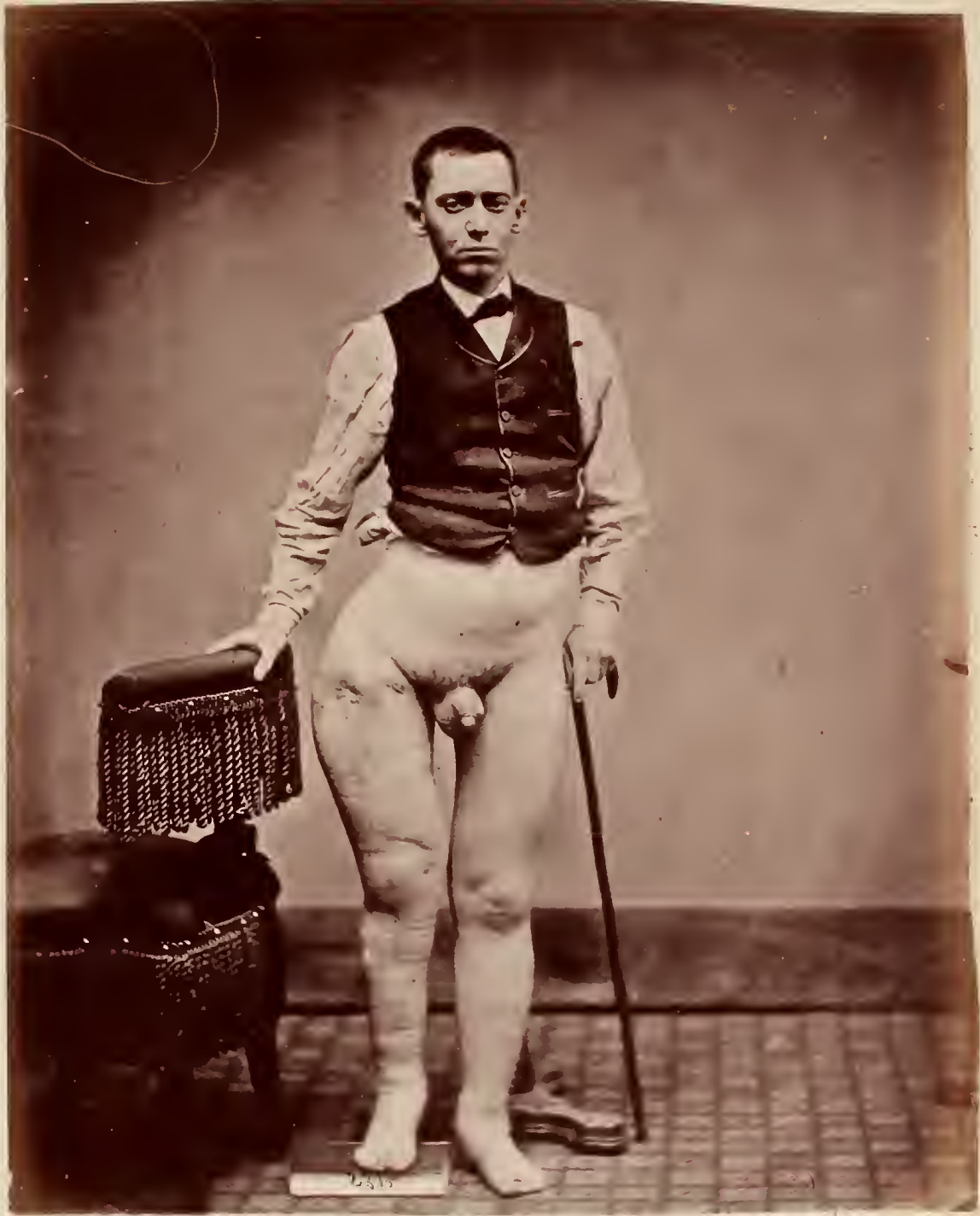Private Thomas Welch, Co. F, 6th Maine Volunteers, aged twenty years, was wounded on November 7, 1863, at Rappahannock Station, Virginia, by a conoidal musket ball, which entered the front aspect of the left thigh in the upper third, fractured the femur, and escaped at a point nearly opposite. When admitted to Armory Square Hospital, on November 9, 1863, his limb was slung in a frame, with a weight suspended from the foot, which was removed a few days afterward. Two pieces of bullet were extracted, and cold water dressings applied. On May 26, 1864, he was sent to Chester Hospital, Pennsylvania, and on March 7, 1865, was transferred to the Satterlee Hospital at Philadelphia. He was discharged the service March 29, 1865, by expiration of enlistment, and pensioned. On August 29, 1866, Pension Examiner J. Cummiskey reported the injured limb shortened some three inches, and completely ankylosed at the knee joint. Exfoliation was still going on and the patient suffered much pain, and was obliged to use a crutch, the limb being entirely useless. On August 20, 1869, at the time the photograph was taken, he had good use of the limb; but it felt weaker than the other, and was apt to swell if he walked much. He then walked without a cane, and was an inmate of the National Asylum for Disabled Volunteer Soldiers at Augusta, Maine.

Photographed at the Army Medical Museum.

BY ORDER OF THE SURGEON GENERAL:

GEORGE A. OTIS.

*Ass't Surg. U. S. A., Curator A. M. M.*



SURGICAL PHOTOGRAPH NO. ....

*Prepared under the supervision of*  
ASSISTANT SURGEON GEORGE A. OTIS, U. S. A.  
BY ORDER OF THE SURGEON GENERAL.

WAR DEPARTMENT,  
SURGEON GENERAL'S OFFICE, ARMY MEDICAL MUSEUM

Surgeon General's Office.  
ARMY MEDICAL MUSEUM.

PHOTOGRAPH No. 236. *Partial Recovery after Compound Comminuted Fracture of the Femur by a Conoidal Bullet.*

Private Michael Murtha, Co. H, 159th New York Volunteers, aged eighteen years, was wounded on April 14, 1863, in an engagement at Irish Bend, Louisiana, by a conoidal musket ball, which entered the right thigh anteriorly in its upper third, and escaping at a point nearly opposite, lodged in the pants. On the 17th, he was admitted to the Marine Hospital at New Orleans, where the limb was treated by sand bags, and by manual extension once daily. It united in bad shape, and another Surgeon coming in charge, it was rebroken, and Boyer's splint was applied. He was able to bear his weight on it about eight months afterward. On March 9, 1864, he was transferred to the Veteran Reserve Corps, the limb having shortened three inches. On August 24, 1864, he was admitted, for chronic ulcer, to the Augur Hospital at Alexandria, Virginia, from Camp Distribution, and on August 27th was transferred to the Second Division Hospital at the same place. He was discharged the service May 31, 1865, and was pensioned. On July 28, 1865, Pension Examiner Charles Rowland reported that the patient suffered from a large abscess, from which many pieces of bone had been extracted. He was quite lame, being obliged to walk with a crutch. His habits were moral and temperate. His disability is rated total and permanent. On August 14, 1869, at which time a photograph was taken, the patient was an inmate of the National Asylum for Disabled Volunteer Soldiers at Augusta, Maine. The wound had not healed, and the thigh discharged in four places, but, with the assistance of a cane, he was able to walk comfortably.

Photographed at the Army Medical Museum.

BY ORDER OF THE SURGEON GENERAL:

GEORGE A. OTIS,  
*Ass't Surg. U. S. A., Curator A. M. M.*



**SURGICAL PHOTOGRAPH NO. ....**

*Prepared under the supervision of*  
ASSISTANT SURGEON GEORGE A. OTIS, U. S. A.  
BY ORDER OF THE SURGEON GENERAL.

**WAR DEPARTMENT.**  
SURGEON GENERAL'S OFFICE, ARMY MEDICAL MUSEUM.

Surgeon General's Office.  
ARMY MEDICAL MUSEUM.

PHOTOGRAPH No. 237. *Successful Excision of the Left Tibia.*

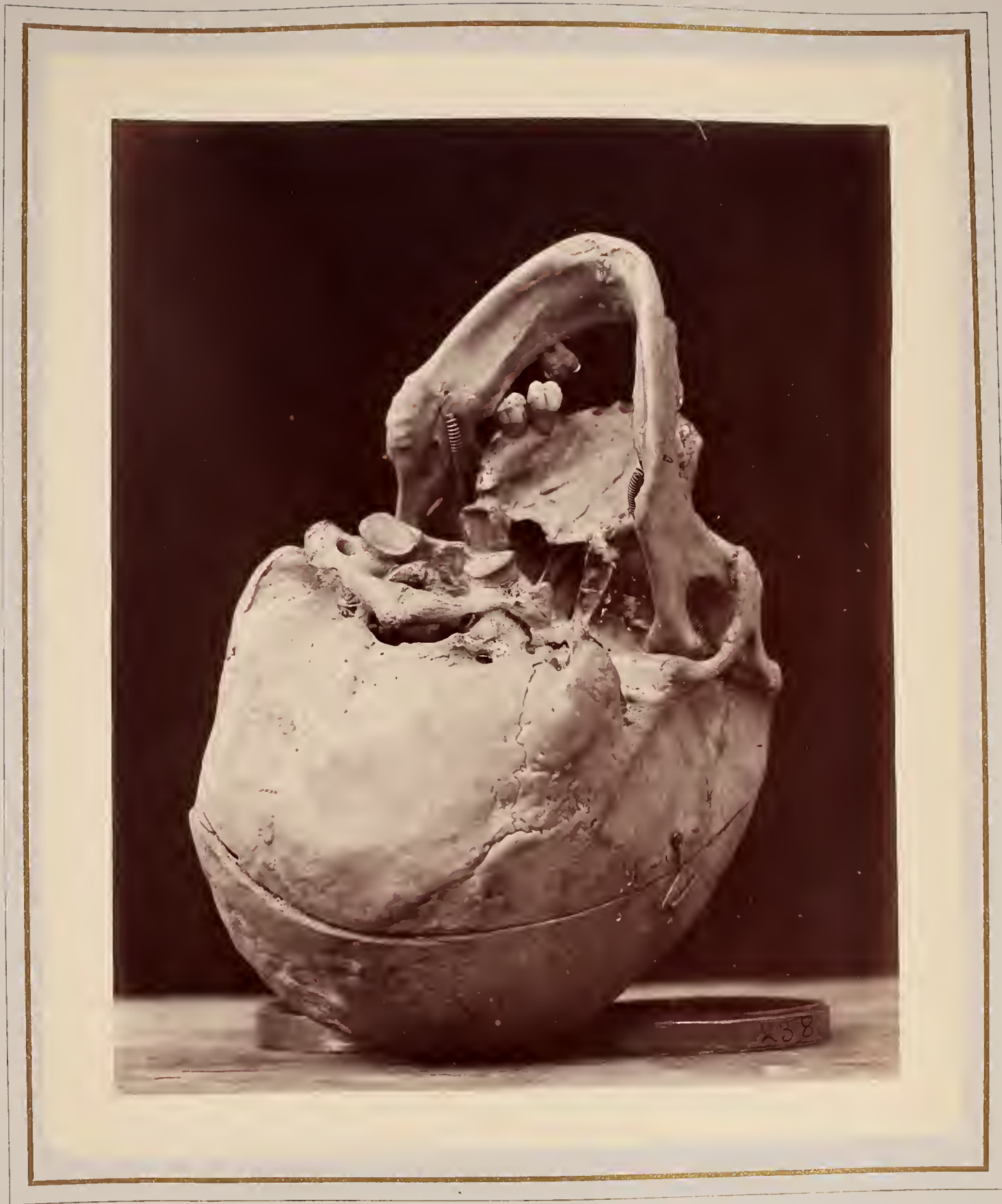Lieutenant O. R. Tyler, Battery I, 2d Connecticut Heavy Artillery, was wounded at Opequan Creek, near Winchester, Virginia, on September 19, 1864, by a conoidal musket ball, which fractured and comminuted the left tibia in the middle third. On the same day he was sent to the depôt field hospital, where Surgeon Henry Plumb, 2d Connecticut Heavy Artillery, by a linear incision along the inner anterior aspect, excised three inches of the bone, which was much comminuted. The patient's general condition was satisfactory; simple dressings were applied. On November 12th he was transferred to the hospital at Frederick, Maryland, where, on December 15th, the missile and fragments of bone were removed. By January 14, 1865, when he was furloughed, there had been no bony deposit in the interspace. He was discharged from service March 9, 1865. In June, 1865, Dr. E. D. Hudson, who furnished the patient an apparatus for supporting the limb, reported that there was no shortening of the leg, but that it was considerably atrophied, with lateral excurvature; the head of the fibula was partially detached by relaxation of the ligaments, and the flexor muscles of the foot were impaired. A thin osseous tissue, not continuous or united, supplied the place of the missing bone, but afforded no support.

Photographed at the Army Medical Museum.

BY ORDER OF THE SURGEON GENERAL:

GEORGE A. OTIS,  
*Ass't Surg. U. S. A., Curator A. M. M.*





**SURGICAL PHOTOGRAPH NO.**

*Prepared under the supervision of*  
ASSISTANT SURGEON GEORGE A. OTIS, U. S. A.  
BY ORDER OF THE SURGEON GENERAL.

**WAR DEPARTMENT,**  
SURGEON GENERAL'S OFFICE, ARMY MEDICAL MUSEUM.

Surgeon General's Office,  
ARMY MEDICAL MUSEUM.

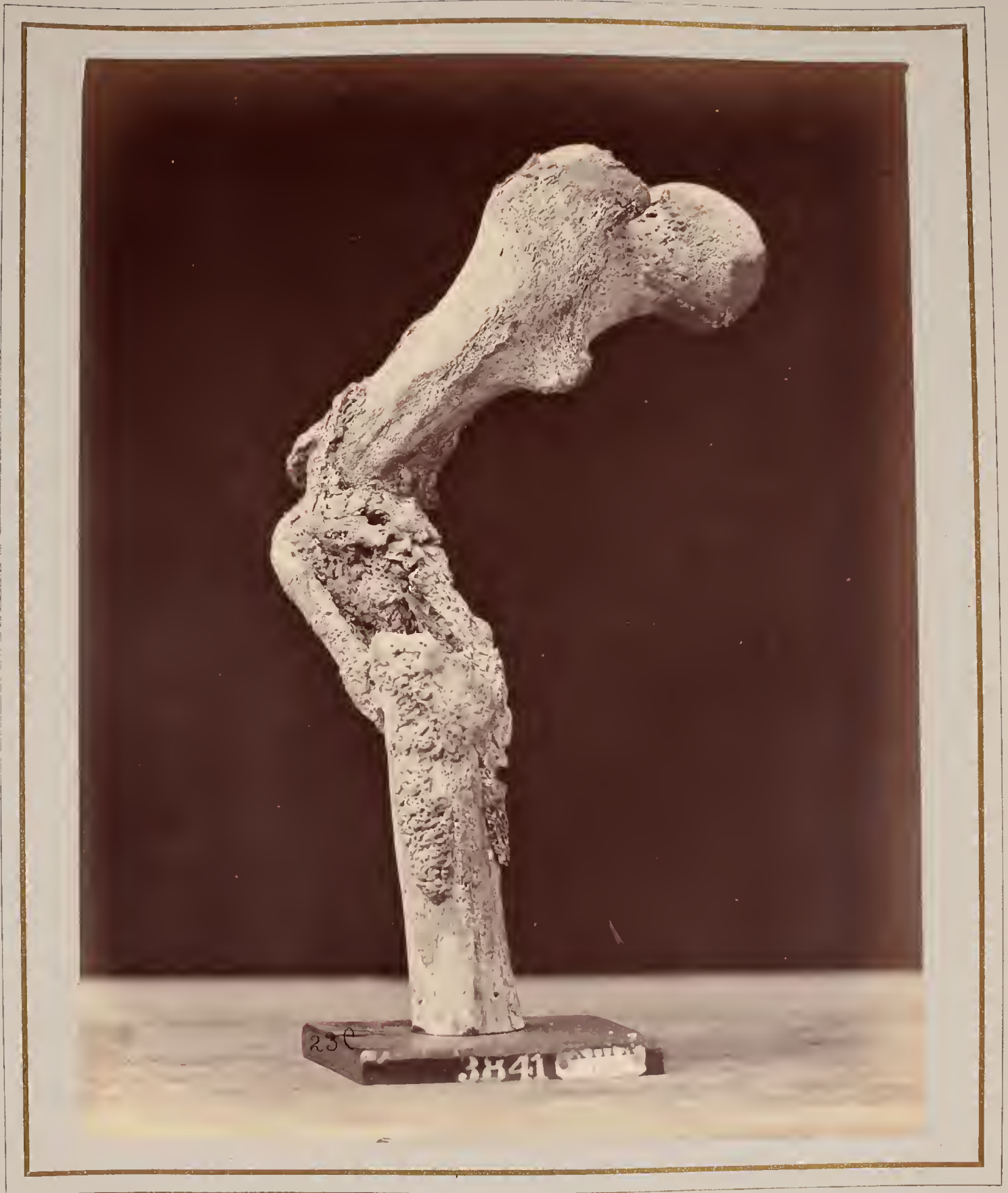PHOTOGRAPH No. 238. *A Cranium, with the Atlas luxated to the Right and Firmly Ossified to the Occipital Condyles.*

The specimen is 5119 of the Surgical Section, and formerly was No. 115 of the Gibson Collection.

Photographed at the Army Medical Museum.

BY ORDER OF THE SURGEON GENERAL:

GEORGE A. OTIS,  
*Ass't Surg. U. S. A., Curator A. M. M.*



**SURGICAL PHOTOGRAPH NO. . . . .**

*Prepared under the supervision of*  
ASSISTANT SURGEON GEORGE A. OTIS, U. S. A.  
BY ORDER OF THE SURGEON GENERAL.

**WAR DEPARTMENT.**  
SURGEON GENERAL'S OFFICE, ARMY MEDICAL MUSEUM.

**Surgeon General's Office.**  
—♦—  
**ARMY MEDICAL MUSEUM.**  
—♦—

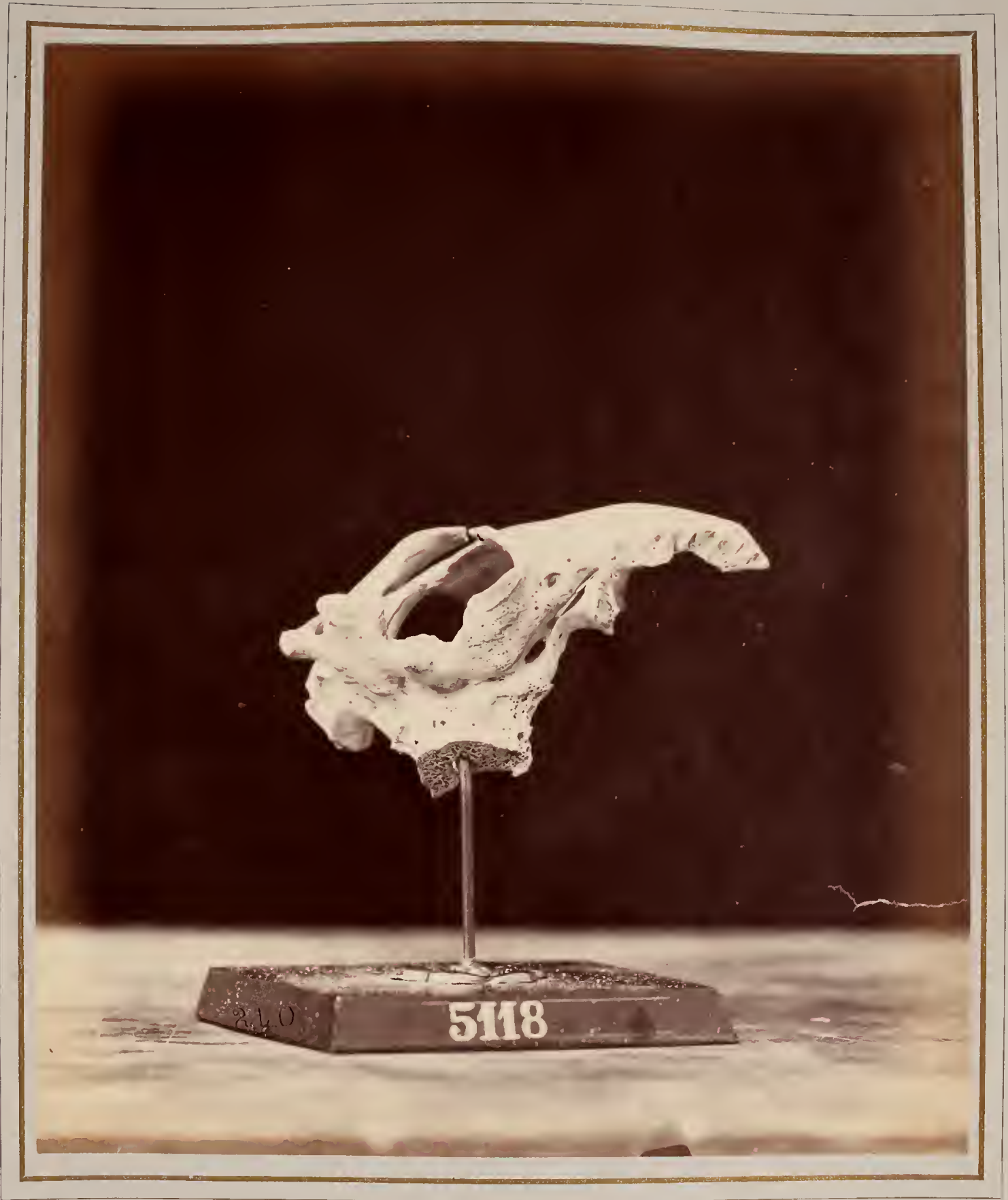PHOTOGRAPH No. 239 *Shaft and Proximal Extremity of the Left Femur, showing Lateral Deformity, with Necrosis and Exfoliation, the Result of a Gunshot Wound.*

Private M. D. Powell, Co. H, 26th Alabama Regiment, aged twenty-two years, was wounded at Antietam, September 17, 1862, by a missile, which produced a compound comminuted fracture of the upper third of the left femur and lodged. He was admitted to the Hospital at Frederick, Maryland, January 2, 1863. No apparatus was applied; but the limb was placed in easy position under a pillow, the missile was extracted, and nitric acid was applied to the sloughing wound. On January 26th, the wound had an unhealthy appearance, at first supposed to be gangrenous. The patient had a troublesome cough, for which a stimulating cough-mixture and cups to chest were prescribed. His general condition improved until erysipelas set in, which was ineffectually treated by the expectant plan. He died March 16, 1863, from exhaustion. At the autopsy, the fracture was found united at an angle of forty-five degrees; the hip-joint contained pus, and the cartilage of the acetabulum was softened. There was bronchitis in the upper lobe of the right lung, and a calcareous deposit, of buckshot size, was found in the middle lobe. The heart and liver were fatty, and in the pelvis of the kidneys phosphatic deposits were found. The specimen, which is No. 3841, Surgical Section, was contributed by Assistant Surgeon R. F. Weir, U. S. A.

**Photographed at the Army Medical Museum.**

BY ORDER OF THE SURGEON GENERAL:

GEORGE A. OTIS,  
*Ass't Surg. U. S. A., Curator A. M. M.*



**SURGICAL PHOTOGRAPH NO.**

*Prepared under the supervision of*  
ASSISTANT SURGEON GEORGE A. OTIS, U. S. A.  
BY ORDER OF THE SURGEON GENERAL.

**WAR DEPARTMENT.**  
SURGEON GENERAL'S OFFICE, ARMY MEDICAL MUSEUM.

Surgeon General's Office.  
ARMY MEDICAL MUSEUM.

PHOTOGRAPH NO. 240. *Dislocation of the Occipital Bone from the Atlas, with Osseous Anchylosis.*

This specimen, which is No. 5118 of the Surgical Section, is marked Paris, 1847, and, formerly, was No. 155 of the Gibson Collection. The atlas is dislocated laterally and to the right, the lateral masses and right laminae being strongly united to the occipital bone. The rudimentary spinous process is wanting, and the laminae do not unite.

Photographed at the Army Medical Museum.

BY ORDER OF THE SURGEON GENERAL:

GEORGE A. OTIS,  
*Ass't Surg. U. S. A., Curator A. M. M.*



**SURGICAL PHOTOGRAPH NO.**

*Prepared under the supervision of*  
ASSISTANT SURGEON GEORGE A. OTIS, U. S. A.  
BY ORDER OF THE SURGEON GENERAL.

**WAR DEPARTMENT.**  
SURGEON GENERAL'S OFFICE, ARMY MEDICAL MUSEUM.

# Surgeon General's Office.

## ARMY MEDICAL MUSEUM.

PHOTOGRAPH No. 241. *Tubular Sequestra from Two Stumps of Femur after Amputation*

Private John Nash, Co. G, 143d Pennsylvania Volunteers, aged twenty-one years, was wounded in an engagement at North Anna River, Virginia, May 24, 1864, by a ball which fractured the right knee-joint. On the same day, he was admitted to the hospital of the Fourth Division, Fifth Corps; thence, was conveyed on a transport to Washington, and, admitted, on May 29th, to the Armory Square Hospital. While on the way, on the 28th, his thigh had been amputated at the lower third. By December 21st, he was pronounced convalescent, and was transferred to Judiciary Square Hospital. Suppuration indicating the presence of dead bone, Acting Assistant Surgeon F. H. Hill, on April 9, 1865, removed the sequestrum. The patient was discharged from service on June 22, 1865, and pensioned, his disability being rated total. The sequestrum was contributed to the Army Medical Museum by Surgeon E. Griswold, U. S. V., and is numbered 144 of the Surgical Section. It is about eight inches long and completely tubular, and is represented on the right of the photograph.

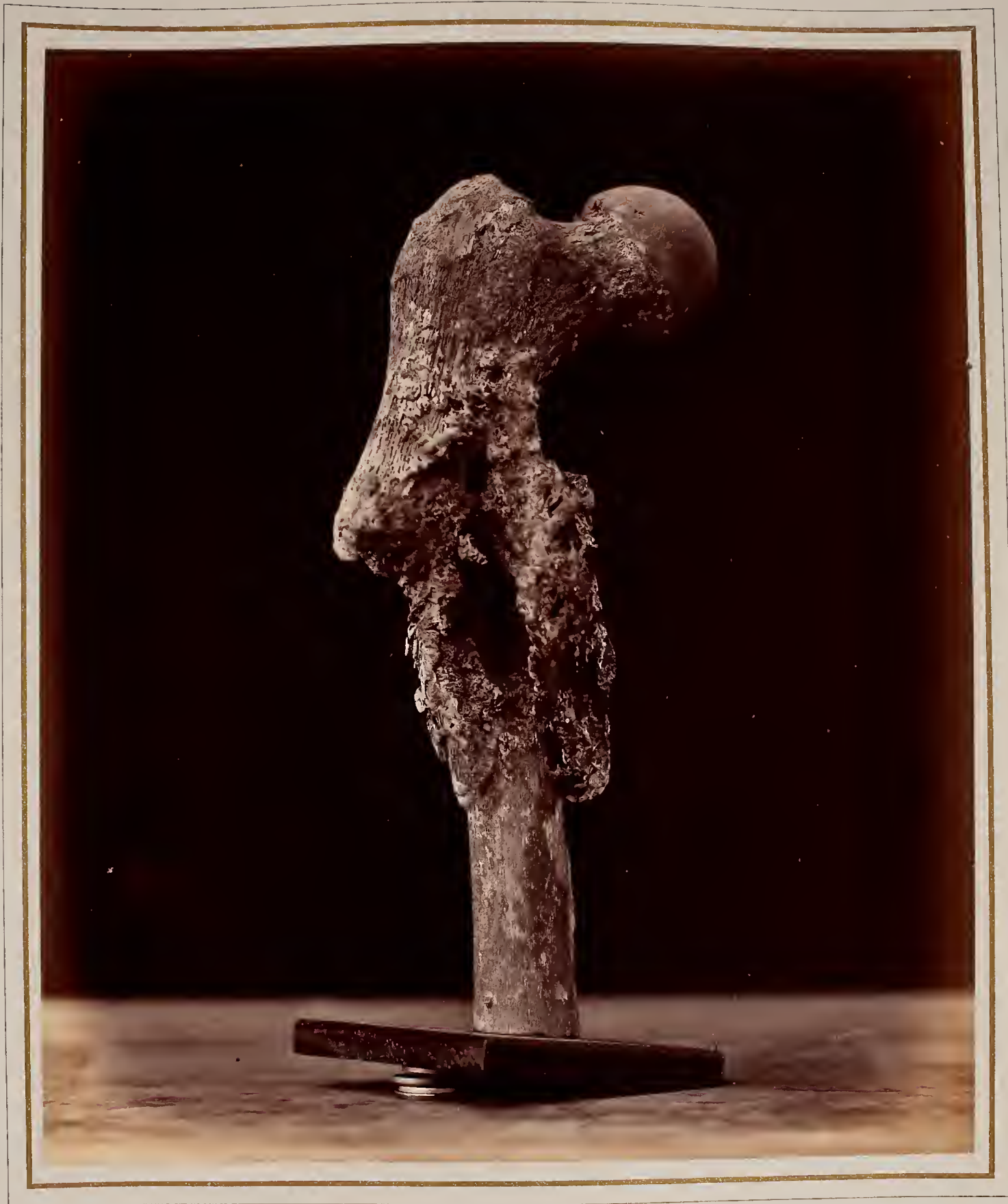Private John Glassie, Co. B, 63d New York Volunteers, aged twenty-two years, was wounded at Cold Harbor, Virginia, June 3, 1864, by a canister-shot which fractured the left ankle-joint. On the same day, he was admitted to the hospital of the First Division, Second Corps, where Surgeon P. E. Hubon, 28th Massachusetts Volunteers, amputated the lower third of the leg. On the 11th, he arrived at Washington, and was admitted to the Emory Hospital, where, on the 25th, Surgeon N. R. Mosely, U. S. V., amputated the lower third of the thigh by the bi-lateral flap operation. Extensive sloughing ensued, the femur became diseased, and gangrene supervened. An abscess that had formed, was opened on October 12th, and poultices were applied. On November 1st, the stump was much swollen, and was still discharging; and on March 11, 1865, when he was transferred and admitted to Central Park Hospital, New York City, the end of stump was reported red and inflamed, with three sinuses leading to necrosed bone. On March 19th, Acting Assistant Surgeon S. Teats made an incision on face of stump and removed the sequestrum. The patient was discharged from service on August 15, 1865, and pensioned, his disability being rated total. The sequestrum was contributed to the Army Medical Museum by the operator, and is No. 3100 of the Surgical Section. It is eight inches long, is tubular, and is represented on the left of the photograph.

Photographed at the Army Medical Museum.

BY ORDER OF THE SURGEON GENERAL:

GEORGE A. OTIS,  
*Ass't Surg. U. S. A., Curator A. M. M.*





SURGICAL PHOTOGRAPH NO. 1000

*Prepared under the supervision of*  
ASSISTANT SURGEON GEORGE A. OTIS, U. S. A.  
BY ORDER OF THE SURGEON GENERAL.

WAR DEPARTMENT.  
SURGEON GENERAL'S OFFICE, ARMY MEDICAL MUSEUM

**Surgeon General's Office.**  
—+—  
**ARMY MEDICAL MUSEUM.**  
—+—

PHOTOGRAPH No 242. *Upper Portion of the Right Femur showing its Condition Eleven Months after Fracture by a Conoidal Musket Ball.*

Lieutenant George A. Connor, Co. A, 7th West Virginia Volunteers, aged twenty-four years, was wounded at Ream's Station, August 25, 1864, by a conoidal musket ball, which fractured the femur at the junction of the middle with the upper third, and caused considerable hæmorrhage. His limb was placed on a lateral splint whilst on the field. On August 28th, he was admitted to the Armory Square Hospital at Washington in a very feeble condition and suffering intense pain. Stimulants and anodynes were freely administered, and the limb was placed in a fracture box without extension. On November 5th, the patient had intermittent fever, which, continuing five days, was checked by quinine. On April 1st, the femur had united, but sinuses extended to the necrosed bone which the patient at first refused to have removed; however, becoming much emaciated and daily losing strength, he consented to the operation, and, on June 24th, Surgeon D. W. Bliss, U. S. V., removed portions of necrosed bone and fragments of lead. He suffered greatly from the effects of the operation for three days subsequently, when healthy granulations appeared. In the meantime, he was treated expectantly. On July 10th, an uncontrollable diarrhœa set in, and he died from exhaustion on July 31, 1865. The pathological specimen, showing a certain degree of union by foliaceous callus, was contributed, with the history, to the Army Medical Museum by Acting Assistant Surgeon C. B. Porter, and is No. 4382, Surgical Section.

**Photographed at the Army Medical Museum.**

BY ORDER OF THE SURGEON GENERAL:

GEORGE A. OTIS,  
*Ass't Surg. U. S. A., Curator A. M. M.*



SURGICAL PHOTOGRAPH NO. ....

*Prepared under the supervision of*  
ASSISTANT SURGEON GEORGE A. OTIS, U. S. A.  
BY ORDER OF THE SURGEON GENERAL.

**WAR DEPARTMENT.**  
SURGEON GENERAL'S OFFICE, ARMY MEDICAL MUSEUM.

# Surgeon General's Office.

## ARMY MEDICAL MUSEUM.

PHOTOGRAPH No. 243. *Sequestra removed from Femurs after Amputation.*

Private William B. Biddle, Co. K, 138th Pennsylvania Volunteers, aged twenty-seven years, was wounded at Cedar Creek, Virginia, October 19, 1864, by a conoidal musket ball, which struck the external condyle of the left femur and penetrated the knee joint. On the same day, he was admitted to field hospital; his wound was dressed; and, on the 24th, he was transferred to Baltimore, and admitted to the Jarvis Hospital, where Acting Assistant Surgeon B. B. Miles administered ether, and amputated the thigh, at the lower third, by the circular operation. On February 22, 1865, a sequestrum, about four inches long, was removed, and was contributed, by the operator, to the Army Medical Museum, where it is No. 109 of the Surgical Section. The patient was furloughed on March 20th, and, on April 25th, was admitted to the South Street Hospital at Philadelphia. On May 9th, he was sent to the Hospital at Chester, Pennsylvania, where, on July 18, 1865, he was discharged the service and pensioned, his disability being rated at three-fourths.

Private James M. Runyan, Co. H, 59th New York Volunteers, aged sixteen years, was wounded at Antietam, September 17, 1862, by a projectile which struck the right thigh. He was conveyed to the field hospital at the Sherman House, where the wound was considered so serious that the thigh was amputated in the middle third by the circular method. No further details of the case can be found until October 17th, when he was admitted to the hospital at Smoketown, Maryland, suffering from diarrhoea, and the stump, with about two inches of the bone protruding, and covered with maggots, was secreting an ichorous pus, and showing some gangrenous spots. The protruding bone was removed with a chain saw; the diarrhoea was checked in a few days, by the use of injections, and a nourishing diet; the stump was covered with a cold poultice of yeast and charcoal, and as soon as it presented the desired healthy appearance, a dry linen compress was applied. By January 20, 1863, the stump had healed with a slight protrusion of the femur. Attempts were made to remove the sequestrum without instrumental interference, but it was not till March 14th, that the result was successful. The specimen is about five inches long, and was contributed to the Army Medical Museum by the operator, Surgeon B. A. Vanderkief, where it is No. 101 of the Surgical Section. The patient recovered, was discharged from service on May 4, 1863, and was pensioned, his disability being rated total and permanent.

Private Peter Walker, Co. C, 37th Wisconsin Volunteers, aged thirty-eight years, was wounded at Cold Harbor, Virginia, June 18, 1864, by a ball which severely wounded the right knee joint; he also received a gunshot flesh wound of the left thigh. He was admitted to the hospital of the Third Division, Ninth Corps. The injured knee being lacerated and much swollen, Surgeon S. S. French, 20th Michigan Volunteers, amputated the right thigh, at the junction of the lower third, by the circular method. He was sent to Washington, and was admitted to the Emory Hospital on June 24, 1864, where a tubular sequestrum of bone, four inches long was extracted from the stump; but the patient died on August 22, 1864. The sequestrum was contributed to the Army Medical Museum by Surgeon N. R. Mosely, U. S. V., and is numbered 3128 of the Surgical Section.

Private John Frederick, Co. D, 15th Massachusetts Volunteers, aged thirty-five years, was wounded at Bristol Station, Virginia, October 14, 1863, by a fragment of shell, which entered the middle third of the left thigh posteriorly, and, passing directly forwards, produced a comminuted fracture of the femur, with great destruction of the muscular tissue. He lay neglected on the field until the afternoon of the next day, when he was conveyed, a prisoner, to Gordonsville, where the thigh was amputated, by the circular method, at the junction of the upper thirds. On November 8th, he arrived at Annapolis, from Richmond, and was admitted to the First Division Hospital. The patient gave evidence of having endured considerable exposure and neglect, and made the above statement. He complained of diarrhoea and loss of appetite; the wound was open, the skin retracted, and the sawn extremity of the femur protruded an inch and a half; but it was thought advisable to pursue the expectant plan, and, accordingly, the stump was dressed with alcohol, and generous diet was ordered. By December 1st, the diarrhoea was no longer troublesome, his appetite was good, and the stump was granulating finely, and slowly extending towards extremity of bone, one inch, only, remaining exposed. On January 20, 1864, a sequestrum was first detected, but not being sufficiently loose, it was allowed to remain for the present. The thigh gradually enlarged four inches in circumference, and, on the 1st of April, the patient suffering severely from the presence of necrosed bone, he was chloroformed, and Surgeon B. A. Vanderkief, U. S. V., seized the extremity with large forceps, and, by a combined motion of traction and rotation, removed the separated portion, entire. The operation was perfectly successful; and, on May 24, 1864, the patient was discharged the service, and was pensioned for disability, rated at total. The specimen, which is tubular, and nearly five inches long, was contributed, with the history, by Assistant Surgeon W. S. Ely, U. S. V., and is numbered 2232 of the Surgical Section.

Photographed at the Army Medical Museum.

BY ORDER OF THE SURGEON GENERAL:

GEORGE A. OTIS,

Ass't Surg. U. S. A., Curator A. M. M.



SURGICAL PHOTOGRAPH NO. ....

*Prepared under the supervision of*  
ASSISTANT SURGEON GEORGE A. OTIS, U. S. A.  
BY ORDER OF THE SURGEON GENERAL.

**WAR DEPARTMENT.**  
SURGEON GENERAL'S OFFICE, ARMY MEDICAL MUSEUM.

# Surgeon General's Office,

## ARMY MEDICAL MUSEUM.

PHOTOGRAPH No. 244. *Necrosis and Exfoliation and Deposits of Spongy Callus after a Gunshot Fracture of the Left Femur.*

Private John E. Keith, Co. C. 13th Massachusetts Volunteers, aged twenty years, received a gunshot fracture of the lower third of the left femur, at the second battle of Bull Run, August 30, 1862. He lay on the field until September 2d, when he was removed to Washington in a wagon so heavily laden with wounded that the springs were no protection from the jolting of the wagon over the rough roads. The fracture being comminuted and very oblique, the patient suffered intensely during the journey, and when he was admitted to the Ascension Hospital, the lower fragment of the femur was protruding through the external wound to the extent of an inch. After restoratives had been given him, he was etherized and the fracture was coaptated without much difficulty. The limb was then suspended by Smith's anterior splint, and cold water was applied, and tonics with a nutritious regimen were prescribed. At the beginning of the third week abscesses began to accumulate in the inner and posterior lower portion of the thigh, and bursting through the skin in numerous places discharged profusely. The openings were so numerous that the rollers used to confine the splint could not be applied without covering some of them, which necessitated their daily removal, and as the patient could not endure the slightest handling of the limb he was partially etherized every day while the warm weather continued and afterwards every other day, in order to apply clean rollers around the splint and renew the dressings. Liquor sodæ chlorinatæ, diluted with four parts of water was freely used at each dressing, being injected through the openings by a syringe. To add to the discomfort of the patient, about the end of the fifth week gangrene of the integuments of the sacro-lumbar region and the iliac projections set in, and the patient was transferred to a water bed, but now it was found impossible to keep the limb from rolling and causing great agony. The anterior splint was removed, and one similar to Desault's substituted, with a short anterior one, it being impossible to apply them either laterally or posteriorly on account of the number of openings. The fragments remained in apposition rather better by this apparatus; but it was so uncomfortable that it was removed in a few days and there being no hope of union, short splints covered with oiled silk were placed around the thigh, and the leg swung in a fracture box, this being the most comfortable support that could be devised. He died on October 24 1862. The limb was examined six hours after death. The soft parts from the knee to the groin were utterly disorganized. The femur was removed and sent to the Army Medical Museum. The broken extremities were covered with spongy callus; but a cylindrical sequestrum interposed between the fragments, and there was no union.

Photographed at the Army Medical Museum.

BY ORDER OF THE SURGEON GENERAL:

GEORGE A. OTIS,

*Br't Lt. Col. and Ass't Surg. U. S. A., Curator A. M. M.*



SURGICAL PHOTOGRAPH NO. ....

*Prepared under the supervision of*  
ASSISTANT SURGEON GEORGE A. OTIS, U. S. A.  
BY ORDER OF THE SURGEON GENERAL.

WAR DEPARTMENT,  
SURGEON GENERAL'S OFFICE, ARMY MEDICAL MUSEUM

Surgeon General's Office.  
ARMY MEDICAL MUSEUM.

PHOTOGRAPH No. 245. *Upper Portion of the Right Femur fractured by a Conoidal Musket Ball just below the Trochanters, with Profuse Deposit of Callus without Union.*

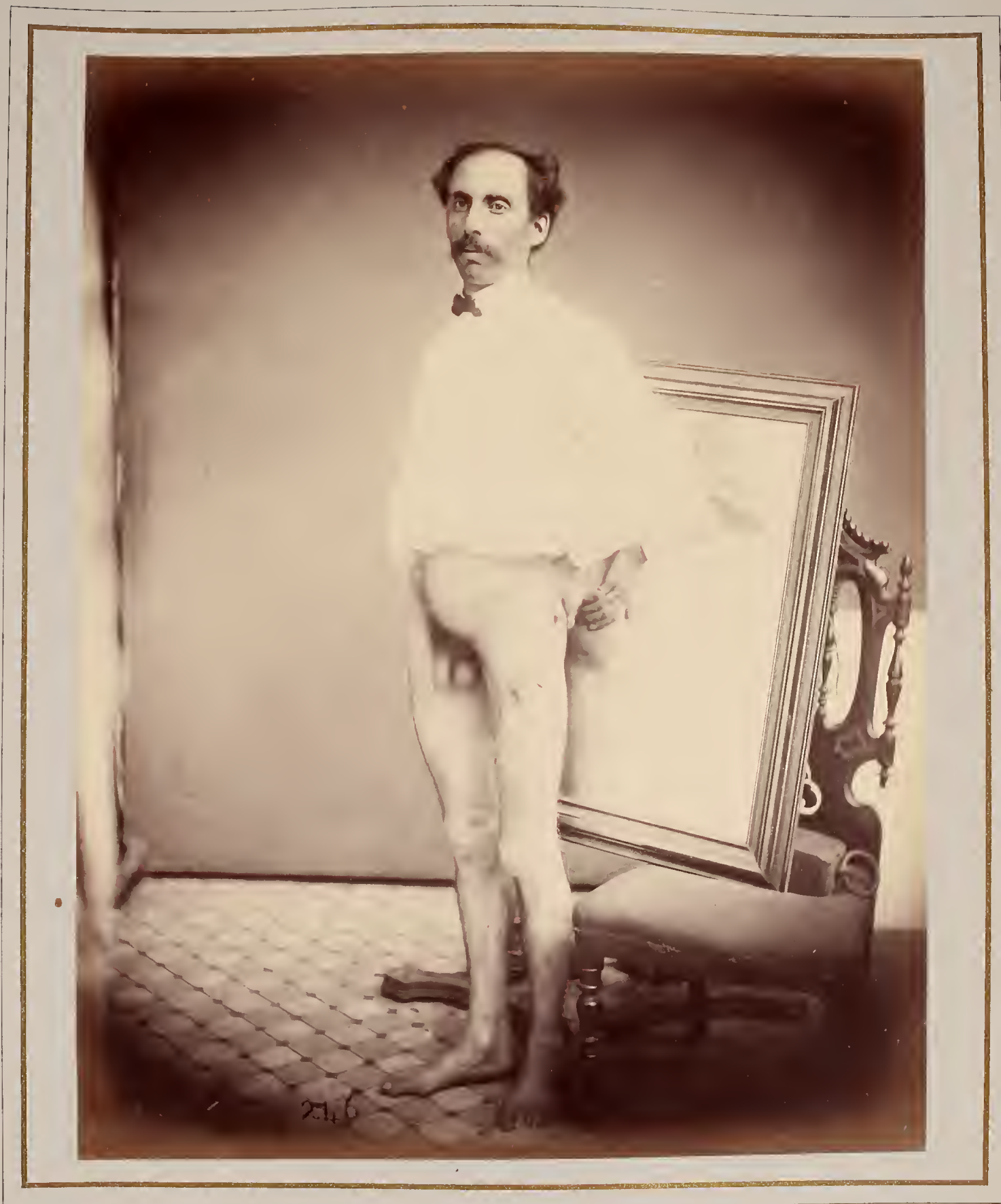Private S. Manley, Co. A, 63d New York Volunteers, aged twenty-six years, was wounded at the battle of Gettysburg, July 2, 1863, by a conoidal musket ball, which fractured the upper third of the right femur. He was sent to Camp Letterman Hospital at Gettysburg on August 4th, where the limb was treated by the double inclined plane and simple dressings. Partial union had taken place. On September 3d there was a profuse discharge from the wound, and the patient was rapidly sinking. There was, also, great shortening of the limb. He died October 8, 1863. The history reports "a complete false joint, the head and socket being covered with a dense, smooth, and apparently fibrous membrane;" but this is not seen in the pathological specimen, which is No. 1935 of the Surgical Section, and was contributed by Acting Assistant Surgeon E. P. Townsend.

Photographed at the Army Medical Museum.

BY ORDER OF THE SURGEON GENERAL:

GEORGE A. OTIS,  
Ass't Surg. U. S. A., Curator A. M. M.





SURGICAL PHOTOGRAPH NO. ....

*Prepared under the supervision of*  
ASSISTANT SURGEON GEORGE A. OTIS, U. S. A.  
BY ORDER OF THE SURGEON GENERAL.

WAR DEPARTMENT.  
SURGEON GENERAL'S OFFICE, ARMY MEDICAL MUSEUM.

Surgeon General's Office.  
—♦♦—  
ARMY MEDICAL MUSEUM.  
—♦♦—

PHOTOGRAPH No. 246. *Gunshot Fracture of Upper Third of Left Femur, treated by Smith's Anterior Splint with Partial Recovery.*

Private Josiah Jones, Co. D, 12th New Hampshire Volunteers, aged twenty-four years, was wounded at Chancellorsville on May 3, 1863, by a missile which fractured the left femur in the upper third. On May 15th he was admitted to the hospital of Whipple's Division, Third Corps; and on June 14th he was sent to the Second Division Hospital at Alexandria, where, on November 20, 1863, he was discharged on surgeon's certificate of disability; afterwards, he was pensioned. A communication from Surgeon Isaac F. Galloupe, U. S. V., dated September 22, 1869, states, that the patient received no appropriate treatment until he arrived at Alexandria, where Smith's Anterior Splint was applied, and the limb kept suspended nearly four months. The upper posterior cicatrix, as shown in the photograph, represents the wound of entrance; the one below it, the location of the last fistulous opening which closed in November, 1868, after discharging, from time to time, fragments of necrosed bone. The outer scar, in front, indicates the wound of exit; the remaining two, the result of abscesses.

**Photographed at the Army Medical Museum.**

**BY ORDER OF THE SURGEON GENERAL:**

**GEORGE A. OTIS,**  
*Ass't Surg. U. S. A., Curator A. M. M.*



SURGICAL PHOTOGRAPH NO. ....

*Prepared under the supervision of*  
ASSISTANT SURGEON GEORGE A. OTIS, U. S. A.  
BY ORDER OF THE SURGEON GENERAL.

WAR DEPARTMENT.  
SURGEON GENERAL'S OFFICE, ARMY MEDICAL MUSEUM

Surgeon General's Office.  
ARMY MEDICAL MUSEUM.

PHOTOGRAPH NO. 247. *Successful Secondary Amputation at the Hip-Joint, following an Excision of the Head of the Femur for Gunshot Injury.*

Private John Schranz, 7th Austrian Feldjägers, was wounded at the battle of Palestro, May 30, 1859, by a ball which fractured the trochanter of the left femur, the splintering involving the joint, either directly or by exciting traumatic arthritis. The formation of abscesses in the thigh rendered some operative interference necessary, and on November 27, 1859, Dr. Neudörfer, chief surgeon of the Eighth Austrian Army Corps, excised the head, neck, and trochanters of the bone. The operation did not result favorably, and four days subsequently Dr. Neudörfer removed the entire limb by the double flap method. A rapid recovery followed, and on January 1, 1860, the patient was walking about. A photograph, presented to Dr. Otis by Dr. Neudörfer, which now hangs in the Army Medical Museum, was taken April 12, 1868, represents the patient in excellent condition more than eight years after the operation. This photograph is a copy from that referred to. A detailed account of this case will be found in Dr. Neudörfer's *Handbuch der Kreisgeschirurgie*. Leipzig, 1864.

Photographed at the Army Medical Museum.

BY ORDER OF THE SURGEON GENERAL:

GEORGE A. OTIS,

*Br't Lt. Col. and Ass't Surg. U. S. A., Curator A. M. M.*



**SURGICAL PHOTOGRAPH NO.** .....

*Prepared under the supervision of*  
ASSISTANT SURGEON GEORGE A. OTIS, U. S. A.  
BY ORDER OF THE SURGEON GENERAL.

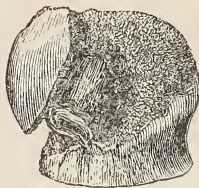
**WAR DEPARTMENT.**  
SURGEON GENERAL'S OFFICE, ARMY MEDICAL MUSEUM.

# Surgeon General's Office.

## ARMY MEDICAL MUSEUM.

PHOTOGRAPHS No. 248, 260, AND 261. *Successful Secondary Excision of the Head of the Femur for Gunshot Injury.*

These three photographs illustrate the case of Private C. F. Read, Co. I, 37th Infantry, who received a gunshot fracture of the head of the left femur, while on picket, sixty miles from Fort Stanton, New Mexico, June 8, 1868. The nature of the injury to the bone will be understood from the adjacent wood cut, copied from the specimen contributed to the Museum by the operator, Assistant Surgeon J. R. Gibson, U. S. Army, and numbered 5576, Section 1, A. M. M. The case is very fully detailed in the Report in Circular No. 2, S. G. O., 1869, page 117. The operation was performed on August 14, 1868, through a T shaped incision. By November 20, the patient was able to walk about the hospital building, and the further progress of the case was as rapid as it was favorable. Early in 1869, this soldier was discharged from the service. He came across the plains by the next train, and in September, 1869, reported at the Surgeon General's Office, where the photograph, No. 248, was taken. At that time the patient's general health was excellent. The cicatrix was perfectly firm and sound, and the strength of the ligamentous attachments and the amount of control over the movements of the limb were very remarkable. He could bear much weight on the limb. Assistant Surgeon Otis, U. S. Army, who was instructed to recommend a suitable apparatus, suggested one; but advised that he should not use it at present, but should continue to exercise the limb cautiously for some months, to increase by exercise the strength of the muscles and ligamentous attachments, and the freedom of the newly formed joint. The next week Read went to New York, and the apparatus proposed, and figured in photograph 261, was ingeniously adapted by Dr. E. D. Hudson. In the summer of 1870, it was reported that this man could walk very comfortably with a cane, either with or without his apparatus.



**Photographed at the Army Medical Museum.**

BY ORDER OF THE SURGEON GENERAL:

**GEORGE A. OTIS,**

*Bo't Lt. Col. and Ass't Surg. U. S. A., Curator A. M. M.*



SURGICAL PHOTOGRAPH NO. ....

*Prepared under the supervision of*  
ASSISTANT SURGEON GEORGE A. OTIS, U. S. A.  
BY ORDER OF THE SURGEON GENERAL.

WAR DEPARTMENT.  
SURGEON GENERAL'S OFFICE, ARMY MEDICAL MUSEUM.

# Surgeon General's Office.

## ARMY MEDICAL MUSEUM.

PHOTOGRAPH No. 249.

The figure on the left of the group represents a section of the left radius and ulna, showing a fracture of each, for which amputation was performed. The ulna is transversely fractured, with necrosis of the borders; the radius is broken into four pieces. The patient was B. F. Surby, a civilian attaché of the army, who was wounded at Fredericksburg, on December 14, 1862, by a projectile which produced the above described injury. He was sent to the Douglas Hospital at Washington on the 26th, where, on December 29th, the forearm was amputated, just below the elbow, by Surgeon Peter Pineo, U. S. V. The patient recovered; and on September 29, 1865, he visited the Army Medical Museum, when the stump, which was in excellent condition, was photographed. The specimen is No. 711 of the Surgical Section, and was contributed by the operator.

The figure on the right represents the upper portion of the right radius and ulna fractured in their upper thirds. A ball has apparently passed between the two, fracturing the radius in an irregularly transverse manner, and chipped off two inches from the posterior surface of the ulna. A longitudinal fissure extends one and a half inches on the posterior surface of the radius, and the borders of the fracture are necrosed. The patient was Thomas A. Martin, a private of Co. G, 91st New York Volunteers, aged twenty-two years, who was wounded at the South Side Railroad on March 30, 1865. He was sent to Philadelphia, and was admitted to the Mower Hospital on April 7, 1865. After his admission several slight hæmorrhages took place, and, on the evening of April 16th, a profuse one occurred from the ulnar artery, high up, which necessitated ligation of the brachial artery in its lowest third. On the 18th, the hæmorrhage recurring, led to the conclusion that the artery had bifurcated above the point of the ligature; and, as the prospect of checking the hæmorrhage was unfavorable, and the injury to the bones and soft parts extensive, amputation at the middle third of humerus, by the circular method, was decided on, and was, accordingly, immediately performed. The patient reacted well. The case progressed favorably, and, by June 6th, the stump had nearly healed, it being kept open only by a slight exfoliation from the end of the bone. A dissection of the amputated arm confirmed the opinion held in reference to the artery: two large trunks had formed, showing bifurcation above the point of ligation. On August 17, 1865, the patient was sent to the head-quarters of his regiment to be mustered out. The specimen is No. 1588 of the Surgical Section, and was contributed, with the history, by Acting Assistant Surgeon W. S. Hendrie.

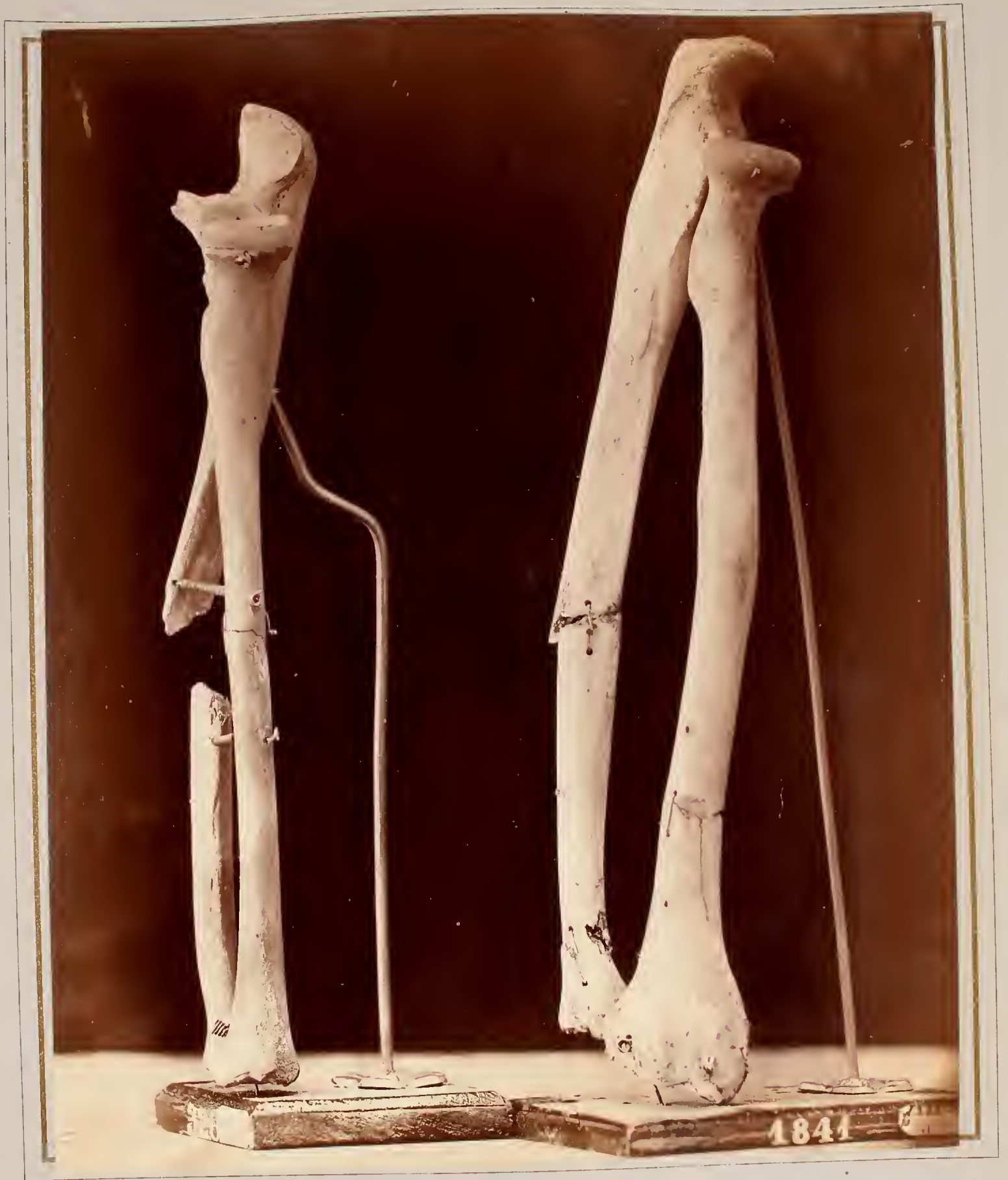The central figure represents the lower two-thirds of the left radius and ulna, apparently amputated. About two inches of the ulna in the lowest third is wanting; and the radius, directly opposite, is transversely fractured without displacement, (probably by the same missile nearly spent,) with slight fissuring, extending, posteriorly, to the styloid process. The specimen is No. 2371 of the Surgical Section; the contributor and history are unknown.

Photographed at the Army Medical Museum.

BY ORDER OF THE SURGEON GENERAL:

GEORGE A. OTIS,  
*Ass't Surg. U. S. A., Curator A. M. M.*





**SURGICAL PHOTOGRAPH NO. ....**

*Prepared under the supervision of*  
ASSISTANT SURGEON GEORGE A. OTIS, U. S. A.  
BY ORDER OF THE SURGEON GENERAL.

**WAR DEPARTMENT.**  
SURGEON GENERAL'S OFFICE, ARMY MEDICAL MUSEUM

# Surgeon General's Office.

## ARMY MEDICAL MUSEUM.

PHOTOGRAPH No. 250. *Specimens exhibiting Comminuted Fractures of the Right and Left Forearm*

The Left shows a transverse fracture of the radius in the middle third, without displacement. The ulna is fractured, with the loss of one inch in the middle third. This specimen, in which no pathological changes are noticeable, was contributed by Surgeon J. E. Summers, U. S. A., and is No. 320 of the Surgical Section.

The Right shows a transverse fracture of the radius in the lower third, with both fragments longitudinally fissured. The ulna has two transverse fractures; one in the middle third, and one just above the lower extremity. These bones are the result of an unsuccessful amputation, performed on Private A. P. Bush, Troop F, 1st Massachusetts Cavalry, aged twenty-nine years, who was wounded at Bristow Station, Virginia, in October, 1863, by a solid shot, which caused the above mentioned injury. On October 15th, he was admitted to the First Division Hospital at Alexandria, in a feeble and exhausted condition. The limb was extensively swollen, and the patient suffered intense pain. Three days subsequently, the arm was amputated in the middle third by the circular operation. On the 23d, he seemed to improve; but, on the 25th, the flaps sloughed apart. On the 29th, the stump was granulating finely, and he continued to improve. On November 1st, the patient had a violent chill, which, lasting twenty minutes, was followed by a fever of two hours duration. The chills recurred on the 6th, 7th and 8th, and, by the 19th, he was in a very low condition. On the 20th, he was much improved, and the wound looked finely; but he did not seem to rally sufficiently to warrant hopes of his recovery. Pyæmia supervened, and death occurred on November 21, 1863. The autopsy revealed an abscess at the shoulder joint, filled with six ounces of pus. The abdominal viscera were normal, with the exception of the stomach, which was highly congested. This specimen, exhibiting no noticeable pathological changes, was contributed by Surgeon E. Bentley, U. S. V., and is No. 1841 of the Surgical Section.

**Photographed at the Army Medical Museum.**

BY ORDER OF THE SURGEON GENERAL:

GEORGE A. OTIS,

*Ass't Surg. U. S. A., Curator A. M. M.*















Harvard University

Library of  
The Medical School



The Gift of

